

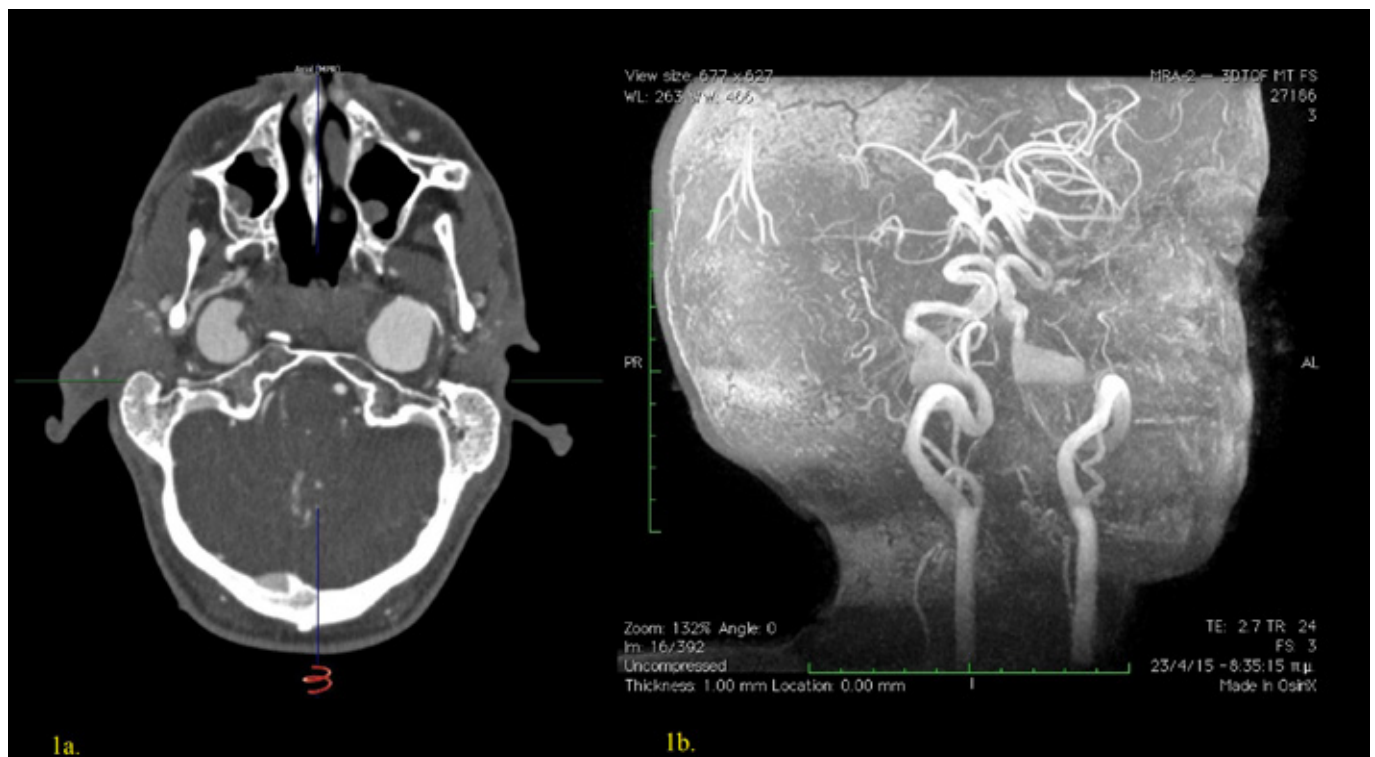
## VASCULAR IMAGE

# Bilateral giant internal carotid artery aneurysms of the cavernous segment in a young male

Stylianos Koutsias<sup>1</sup>, Konstantinos Spanos<sup>2</sup>, Athanasios D. Giannoukas<sup>2</sup>

<sup>1</sup>Vascular Surgery Department, University Hospital of Larissa, Faculty of Medicine, School of Health Sciences, University of Thessaly, Larissa, Greece

<sup>2</sup>Department of Surgery, Vascular Surgery Unit, School of Medicine, University of Ioannina, Ioannina, Greece



A 21-year old male, with known history of neurofibromatosis type 1, presented to the emergency department with high blood pressure (180/60 mmHg) and headache. Physical examination revealed a bruit and a palpable mass in the neck area bilaterally. Duplex scanning showed bilateral severe carotid artery tortuosity and a suspicion of bilateral internal carotid artery aneurysms in a more distal part of the arteries. A computed tomography angiography confirmed (Image 1a) the presence of bilateral giant internal carotid aneurysms (right side 26mm, left side 34mm in diameter) of the cavernous segment. A magnetic resonance angiography (Image 1b) was undertaken at a later stage to help in the planning of their treatment, however patient denied treatment. This pathology is rare; open repair is accompanied with high morbidity and mortality, while endovascular approach has been suggested recently as another option.

Author for correspondence:

**Konstantinos Spanos, MD, MSc, PhD**

Department of Vascular Surgery, University Hospital of Larissa, Faculty of Medicine, School of Health Sciences, University of Thessaly, Larissa, Greece

E-mail: spanos.kon@gmail.com, Tel.: +306948570321

ISSN 1106-7237/ 2019 Hellenic Society of Vascular and Endovascular Surgery Published by Rotonda Publications  
All rights reserved. <https://www.heljves.com>