



Hellenic Society of Vascular
and Endovascular Surgery

Hellenic Journal of Vascular and Endovascular Surgery

HOT TOPICS

Total Endovascular Arch replacement for a Non-A, Non-B Aortic Dissection
Larisa, Greece

Emerging evidence in the diagnosis and management of carotid near-occlusion
Athens, Greece

Acute carotid stent thrombosis
Patras, Greece

PAST EDITORS

First period: Hellenic Vascular Surgery (2007-2014)



Prof. Michael Sechas
Founding Editor
Editor in Chief 2007-2010



Prof. Chris Liapis
Editor in Chief 2011-2014

Second period: Hellenic Journal of Vascular and Endovascular Surgery (2019-)



Prof. Miltos Matsagkas
Founding Editor
Editor in Chief 2019-2021



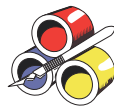Prof. John Kakis
Editor in Chief 2022-



Ass. Prof. Konstantinos Moulakakis
Senior Editor 2022-

BOARD of the HELLENIC SOCIETY of VASCULAR and ENDOVASCULAR SURGERY

- President: **G. Geroulakos**, Athens, Greece
Vice President: **C. Karkos**, Thessaloniki, Greece
Secretary General: **K. Moulakakis**, Patra, Greece
Treasurer: **A. Papapetrou**, Athens, Greece
Secretary: **P. Chatzigakis**, Athens, Greece
Member: **D. Stamos**, Athens, Greece
Member: **T. Bisdas**, Athens, Greece
Member: **T. Papas**, Athens, Greece



Hellenic Society of Vascular and Endovascular Surgery
Feidipidou 8, Athens, Greece
Tel: +30 211 409 46 43
e-mail: info@vascularsociety.gr



Rotonda Publications
8 Kamvounion Str, 54621 Thessaloniki, Greece
Tel: +30 210 212 212

Hellenic Journal of Vascular and Endovascular Surgery

EDITOR IN CHIEF

John Kakisis, Athens, Greece

SENIOR EDITOR

Konstantinos Moulakakis, Patras, Greece

ASSOCIATE EDITORS

- Aortic disease: **Spyridon Mylonas, Cologne, Germany**
- Carotid disease: **Christos Karkos, Thessaloniki, Greece**
- Peripheral arteries: **Andreas Lazaris, Athens, Greece**
- Complex Endovascular: **Athanasios Katsargyris, Nurnberg, Germany**
- Venous disease and thrombosis: **Stavros Kakkos, Patras, Greece**
- Vascular access: **George Georgiadis, Alexandroupolis, Greece**
- Basic science: **Efthymios Avgerinos, Piitsburgh, USA**
- Review and Meta-analysis: **George Antoniou, Manchester, UK**
- Technical notes, Short reports: **George Kouvelos, Larissa, Greece**

EXECUTIVE EDITOR

Konstantinos Antonopoulos, Athens, Greece

HJVES AMBASSADOR

Nikolaos Patelis, Athens, Greece

EDITORIAL BOARD

- Tankut Akay**, *Ankara, Turkey*
Christos Argyriou, *Alexandroupolis, Greece*
Christian-Alexander Behrendt, *Hamburg-Eppendorf, Germany*
Christos Bakoyiannis, *Athens, Greece*
Ugur Bengisun, *Ankara, Turkey*
Colin Bicknell, *London, UK*
Theodosios Bisdas, *Athens, Greece*
Dumitru Casian, *Chisinau, Republic of Moldova*
Petros Chadjigakis, *Athens, Greece*
Roberto Chiesa, *Milano, Italy*
Lazar Davidovic, *Belgrade, Serbia*
Sebastian Debus, *Hamburg-Eppendorf, Germany*
Konstantinos Donas, *Munster, Germany*
Hans-Henning Eckstein, *Munich, Germany*
John A. Eleftheriades, *New Haven, USA*
Konstantinos Filis, *Athens, Greece*
Alberto Froio, *Milano, Italy*
Mladen Gasparini, *Izola, Slovenia*
Efstratios Georgakarakos, *Alexandroupolis, Greece*
George Georgiadis, *Alexandroupolis, Greece*
Sotirios Giannakakis, *Athens, Greece*
Christos Ioannou, *Heraklion, Greece*
Michael Jacobs, *Maastricht, The Netherlands*
George Karaolani, *Ioannina, Greece*
Igor Koncar, *Belgrade, Serbia*
Nikolaos Kontopodis, *Herakleion, Greece*
Thomas Kotsis, *Athens, Greece*
Ian Loftus, *London, UK*
Kevin Mani, *Uppsala, Sweden*
Armando Mansilha, *Porto, Portugal*
Germano Melissano, *Milano, Italy*
Gustavo Oderich, *Houston, USA*
Theophanis Papas, *Athens, Greece*
Michail Peroulis, *Ioannina, Greece*
George Pitoulias, *Thessaloniki, Greece*
Natzi Sakalihan, *Liege, Belgium*
Athanasios Saratzis, *Leicester, UK*
Fragiska Sigala, *Athens, Greece*
Dimitrios Stamos, *Athens, Greece*
Alexei Svetlikov, *St Petersburg, Russia*
Zoltán Szeberin, *Budapest, Hungary*
Slobodan Tanasković, *Belgrade, Serbia*
Nikolaos Tsilimparis, *Munich, Germany*
Vasilios Tzilalis, *Athens, Greece*
Georgios Vourliotakis, *Athens, Greece*
Ana-Maria Vrancianu, *Iasi, Romania*
Dimitrios Xanthopoulos, *Athens, Greece*

ADVISORY BOARD

- Nikolaos Besias**, *Athens, Greece*
Dimitrios Christopoulos, *Thessaloniki, Greece*
Konstantinos Dervisis, *Athens, Greece*
Sotirios Georgopoulos, *Athens, Greece*
George Geroulakos, *Athens, Greece*
Athanasios Giannoukas, *Larissa, Greece*
Christos Klonaris, *Athens, Greece*
George Kopadis, *Athens, Greece*
Kiriakos Ktenidis, *Thessaloniki, Greece*
Christos Liapis, *Athens, Greece*
Chrysostomos Maltezos, *Athens, Greece*
Dimitrios Maras, *Athens, Greece*
Antonios Papageorgiou, *Athens, Greece*
Vasileios Papavassiliou, *Athens, Greece*
Konstantinos Papazoglou, *Thessaloniki, Greece*
Nikos Saratzis, *Thessaloniki, Greece*
Ioannis Tsolakis, *Patras, Greece*
Spiridon Vasdekis, *Athens, Greece*

Instructions for authors

Submission

All manuscripts are submitted through the official site of the Journal:

heljves.com

<https://heljves.com/Submit-Paper/>

Submission list:

- Cover letter (word format)
- Manuscript [word format; includes: abstract, main manuscript, table legends, tables, figure legends and figures (optional)]
- Figures (Tiff format; more details in figure files section)

Instructions for authors in detail

Overview

Manuscripts considered for publication must be written in English and structured as a basic or clinical research, editorial, case report, vascular images, letter to the editors, debate with pros

Peer Review

All manuscripts are reviewed initially by the Chief Editor, Executive Editor, and/or their representatives. A submission is rejected outright if the majority opinion finds that (1) the material does not have sufficient merit to warrant further review or (2) the subject matter is outside the scope of the Journal. The submission may also be returned for inadequate presentation or failure to comply with the HJVES's submission instructions.

Authors should read the HJVES Editorial Policies before constructing the manuscript; it contains detailed information about originality, authorship, primacy, research and animal experimentation, patient consent, conflict of interest disclosure, funding, permissions, scientific misconduct, peer review, contributor publishing agreement, and publication.

and cons, technical description on 'how I did it', review, systematic review and meta-analysis. Type of articles and their word count, tables', figures' and references' number are demonstrated in table 1.

Manuscript type	Word count of abstract	Word count of body of the manuscript	Number of figures/ tables	Number of references
Vascular image	NA	200	2	NA
Case report	150	1000	4	10
Letter to the editor	NA	500	1	5
How I did it	150	1500	4	10
Editorial	NA	1000	1	10
Debate: Pros vs. Cons	NA	1000 (each)	1 (each)	10
Basic research	200-300	3500	10	50
Clinical research	200-300	3500	10	50
Review, Systematic review, Meta- analysis	250-350	3500-5000	15	100

Cover Letter

Manuscripts (except correspondence) must be accompanied by a cover letter signed by all authors stating (1) there has been no duplicate publication or submission of any part of the work; (2) all authors have read and approved the manuscript; and (3) there is no financial arrangement or other relationship that could be construed as a conflict of interest. If a potential conflict exists, its nature should be stated in the letter and on the title page for each author involved (see Editorial Policies for a complete explanation).

Title Page File

- Construct a title that does not exceed 50 words.
- List first and last names, highest academic degree(s), affiliations, and email addresses for all authors.
- Give the total word count.
- Acknowledge all sources of financial support (grants, fellowships, equipment, or remuneration of any kind) and any relationships that may be considered a conflict of interest (ie, employment, stock holdings, retainers, paid or unpaid consultancies, patents or patent licensing arrangements, or honoraria) that may pertain to the manuscript (see Editorial Policies, Conflict of Interest).

- Give details of any prior presentation, including meeting name, location, and date.
- List acknowledgments, any shared first authorship, and other author notes.
- Give the name, mailing address, and email address of the corresponding author.

Abstract

- Give a substantive summary of a basic or clinical research article in 300 words or less, and up to 350 words for systematic reviews and meta-analysis, separating the abstract according to Introduction, Methods, Results, and Conclusion. For case reports and 'how I did it' the abstract should be no longer than 150 words and divided into Purpose, Case Report/ Technique and Conclusion.
- Provide up to 5 keywords.

Text

- Text material must be submitted as a single Word document (not a PDF) named the "Main document."
- Organize the text for clinical or basic experimental investigations and systematic review and meta-analysis into sections entitled Introduction, Methods, Results, Discussion, and Conclusion.

sion. Case reports and 'How I did it' require only Introduction, Case Report/Technique, Discussion, and Conclusion. Editorials, letter to the editor, vascular images, and debate with pros and cons may be structured as appropriate for the material.

- ▶ Avoid naming any institution(s) in the work or otherwise identifying the author(s). • Use SI measurements; generic drug names should be used.
- ▶ Define abbreviations and acronyms when they first appear in the text; do not list them at the beginning of the manuscript file.
- ▶ Identify tables and figures using Arabic numerals in parentheses (eg, Table 1, Figure 1).

References

- ▶ Follow the guidelines in the AMA Manual of Style (10th ed., 2007). Do NOT use endnotes or other bibliographic style function for reference lists.
- ▶ Limit to 10 the number of references for a case report/ 'how I did it'/ editorial and debate with pros and cons. Letters may have no more than 5 references. Basic and clinical articles may have up to 50 references, while systematic review and meta-analysis up to 100 references.
- ▶ Number references in the order of appearance in the text. Identify references in the text, tables, and legends as superscript Arabic numerals.
- ▶ List the first 6 authors (last name and initials separated by a comma); use "et al" for 6 or more authors. Abbreviate journal titles according to the style of Index Medicus; formats for the common types of journal citations are: Journal article: authors' names and initials, article title, journal name, year, volume, and inclusive page numbers.

Examples:

Matsagkas MI, Kouvelos G, Spanos K, Athanasoulas A, Giannoukas A. Double fixation for abdominal aortic aneurysm repair using AFX body and Endurant proximal aortic cuff: mid-term results. *Interact Cardiovasc Thorac Surg.* 2017;25:1-5.

Giannoukas AD, Chabok M, Spanos K, Nicolaidis A. Screening for Asymptomatic Carotid Plaques with Ultrasound. *Eur J Vasc Endovasc Surg.* 2016;52:309-12.

- ▶ Cite entire books by giving the author/editor(s), title, edition, city/state of publication, publisher, and year. Example: Ahn SS, Moore WS, eds. *Endovascular Surgery*, 2nd ed. Philadelphia, PA: WB Saunders Co.; 1991.
- ▶ Cite chapters in books giving the author(s), chapter title, editor(s), book title, city/state of publication, publisher, year, and inclusive page numbers. Example: Towne JB. Postintervention surveillance. In: White RA, Fogarty TJ, eds. *Peripheral Endovascular Interventions*. St. Louis, MO: Mosby-Year Book, Inc.; 1996:109-115.

Legends

- ▶ Type all figure and table legends on a separate page of the manuscript file, explaining abbreviations and symbols used in the figure. Previously published figures must be acknowledged and accompanied by written permission from the publisher to reproduce the material if it is copyrighted.
- ▶ Do not use Word's caption function for figure legends or include the actual figures in the manuscript file.

Table Files

- ▶ Use tables to supplement the text, not duplicate it.
- ▶ Insert tables in the text or create/save tables as an image.
- ▶ Format tables using the table formatting function in Word;

elaborate formatting (shading, color) should not be used.

- ▶ Define any abbreviations as the first footnote under the table; list the abbreviations alphabetically.
- ▶ Use footnotes for explanatory material, labeling each with a superscript lower case letter (a-z) in alphabetical order.

Figure Files

- ▶ Number any pictures, charts, graphs, or line art sequentially as figures.
- ▶ Use color judiciously in pictures and graphics. Figures will be printed in grayscale unless color charges are paid. There is no fees for color figures for print/online display.
- ▶ Add arrows and symbols to digitally created images using functions supplied with the imaging program.
- ▶ Do not import images into the text document but transmit each image file separately.
- ▶ Supply all figures in a digital format of suitable quality for printing: TIF for pictures or EPS for graphs and line drawings (to preserve quality when enlarged/zoomed). Image resolution should be at least 300 ppi for color or grayscale images and 600 ppi (preferably higher) for black and white line drawings or graphs. Image size at these resolutions should be no less than 3 inches wide for vertical images and 5 inches wide for horizontally oriented figures. Use a lossless compression algorithm (eg, LZW) that does not degrade the resolution.
- ▶ Convert PowerPoint slides to individual TIF files for upload.

Publication

Accepted manuscripts will be scheduled for publication generally in the order in which they are received after no further author revisions are required and the Journal Contributor's Publishing Agreement has been signed by the corresponding author. The HJVES reserves the right to edit accepted manuscripts to comply with the journal's format, to correct grammatical faults, to remove redundancies, and to improve readability without altering the meaning. Several weeks before the scheduled publication of an article, the Editorial Office will send via email an edited version of the manuscript to the corresponding author for approval. After the author has approved the edited version, the publisher will send a PDF of the page proof by email. At this stage, only correction of typographical errors or mistakes in the presentation of data can be made. Approval/changes to the proof must be returned within 2 days. The HJVES value their relationships with their authors and appreciate author compliance with these instructions.

Scientific Misconduct

The HJVES takes issues of copyright infringement, plagiarism, or other breaches of best practice in publication very seriously. Every effort is made to protect the rights of authors, and claims of plagiarism or misuse of articles published in the journal are always investigated. Equally, the reputation of the journal is protected against malpractice. Submitted articles may be checked using duplication-checking software. Where an article is found to have plagiarized other work or included third party copyright material without permission or with insufficient acknowledgment, or where authorship of the article is contested, the publisher reserves the right to take action including but not limited to publishing an erratum or corrigendum (correction); retracting the article (removing it from the journal); taking up the matter with the head of department or dean of the author's institution and/or relevant academic bodies or societies; banning the author from publication in the HJVES or all journals, or appropriate legal action.

Contents

EDITORIAL

- 117. Artificial Intelligence and e-Learning will shape the future of vascular surgical training**
Nikolaos Patelis^{1,2}, Sean J. Matheiken³
¹ 3rd Department of Vascular Surgery, Metropolitan General, Athens - Greece
² 2nd Department of Vascular Surgery, Laiko General Hospital, Medical School, National & Kapodistrian University of Athens, Greece
³ Department of Vascular Surgery, Ysbyty Glan Clwyd, Betsi Cadwaladr University Health Board, North Wales, LL18 5UJ, United Kingdom

AORTIC DISEASE

- 120. Total Endovascular Arch replacement for a Non-A, Non-B Aortic Dissection**
Konstantinos Tzimkas-Dakis¹, Konstantinos Spanos¹, George Kouvelos¹, George Volakakis¹, Metaxia Bareka², Grigorios Giamouzis³, Eleni Arnaoutoglou², Miltiadis Matsagkas¹
¹ Department of Vascular Surgery, Faculty of Medicine, School of Health Sciences, University of Thessaly, Larissa, Greece
² Department of Anesthesiology, Faculty of Medicine, School of Health Sciences, University of Thessaly, Larissa, Greece
³ Department of Cardiology, Faculty of Medicine, School of Health Sciences, University of Thessaly, Larissa, Greece

CAROTID DISEASE

- 127. Emerging evidence in the diagnosis and management of carotid near-occlusion**
Constantine N. Antonopoulos MD¹, Georgios Tzavellas MD², Vasileios Bouris, MD², Efthymios D. Avgerinos MD², Christos D. Liapis, MD²
¹ Department of Vascular Surgery, National and Kapodistrian University of Athens, Attikon University Hospital, Athens, Greece
² Department of Vascular & Endovascular Surgery, Athens Medical Center, Athens, Greece

- 132. Acute carotid stent thrombosis (ACST): a review study**
Anastasia K. Kouri¹, Konstantinos G. Moulakakis¹, George Geroulakos²
¹ School of Medicine, Department of Vascular Surgery, University Hospital of Patras, Greece
² School of Medicine, National and Kapodistrian University of Athens, Department of Vascular Surgery, Attikon University Hospital, Greece

CASE SERIES

- 142. Emergency management of life-threatening iatrogenic femoral artery injuries - report of four cases**
George Galyfos, Alexandros Chamzin, Georgios Charalampopoulos, Nikolaos Alexakis, Frangiska Sigala, Konstantinos Filis
Vascular Surgery Unit, First Department of Propedeutic Surgery, National and Kapodistrian University of Athens, Hippocraton Hospital, Athens, Greece

CASE REPORT

- 148. Preservation of internal iliac artery by using it as target vessel for distal anastomosis of bifurcated aortic grafts during surgical repair of aorto-iliac aneurysms**
Stella Lioudaki, Nikolaos Kontopodis, George Tzouliadakis, Emmanouil Tavlas, Alexandros Kafetzakis, Christos V. Ioannou
Vascular Surgery Unit, Department of Vascular and Cardiothoracic Surgery, University of Crete, Medical School, Heraklion, Crete, Greece

VASCULAR IMAGE

- 151. Multiple skip incisions technique for two-staged basilic vein transposition: a good alternative to the standard single long incision**
Pavlos Georgiou, Christos Pitros, Andreas Tsimpoukis, Spyros Papadoulas
Vascular Surgery Department, Patras University Hospital, Patras-Greece

FDA APPROVED

Cordis
A Cardinal Health company

Reengineering the art of EVAR



Ultra-low profile



Customisable
tri-modular design



Efficacy and durability
without compromise¹



Few units fit
most anatomies

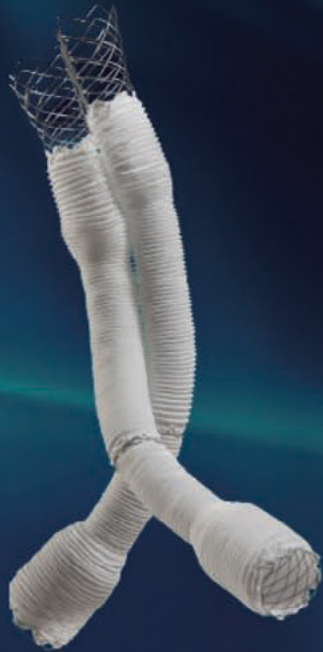

¹ Torsello et al. Safety and effectiveness of the INCRAFT® AAA Stent Graft for endovascular repair of Abdominal aortic aneurysms. JOURNAL OF VASCULAR SURGERY; January 2015, Volume 61, Number 1. Pages 1-8.

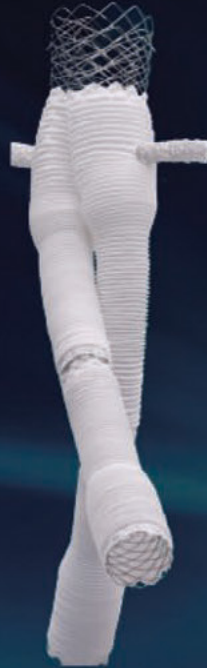The use of the INCRAFT® AAA Stent-Graft System requires that physicians be specially trained in endovascular abdominal aortic aneurysm repair techniques, including experience with high resolution fluoroscopy and radiation safety. Cordis Corporation will provide training specific to the INCRAFT® AAA Stent-Graft System. Contact your Cordis sales representative for availability and ordering. For EMEA Healthcare Professionals. Important information: Prior to use, refer to the Instructions for use supplied with this device for indications, contraindications, side effects, suggested procedure, warnings, and precautions. As part of the Cordis policy of continuous product development, we reserve the right to change product specifications without prior notification.

© Cardinal Health 2016 - All rights reserved. CORDIS, Cordis LOGO, and INCRAFT are trademarks or registered trademarks of Cardinal Health. All other marks are the property of their respective owners. Cordis, Regus Pegasus Airport Center, Pegasuslaan 5, 1831 Diegem, Belgium +32 2 709 2000

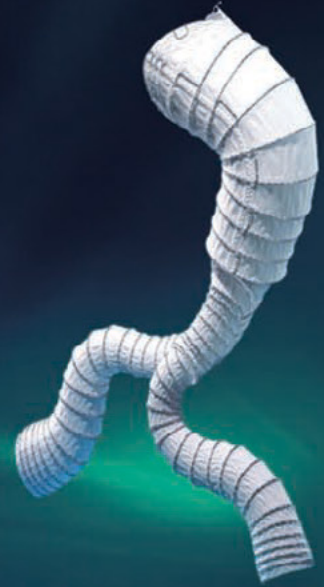From Arch to Iliac -
the broadest **EVAR**, **TEVAR** and **FEVAR**
product portfolio to safely treat your patients



altura™



Fenestrated
altura™



AORFIX™



Hercules



Castor

available by

EDITORIAL

Artificial Intelligence and e-Learning will shape the future of vascular surgical training

Nikolaos Patelis^{1,2}, Sean J. Matheiken³

¹ 3rd Department of Vascular Surgery, Metropolitan General, Athens - Greece

² 2nd Department of Vascular Surgery, Laiko General Hospital, Medical School, National & Kapodistrian University of Athens, Greece

³ Department of Vascular Surgery, Ysbyty Glan Clwyd, Betsi Cadwaladr University Health Board, North Wales, LL18 5UJ, United Kingdom

In the aftermath of the COVID-19 pandemic, vascular e-Learning (VeL) has been shown to be a valuable teaching method for vascular surgeons and trainees¹⁻⁴. Multiple studies have reported a significantly positive appreciation by vascular surgeons and trainees for VeL tools, including webcasts, podcasts, practical skills tutoring, virtual simulations, and online tests^{1,4,5}. This paradigm shift remains a process in progress; however, even as the vascular surgical society and training institutions gently grapple with the promise and potential of

VeL, artificial intelligence (AI) has announced itself as a radical 'game-changer' in domains of medical training, education and practice. Medical AI is projected to grow from a US\$14.6b market in 2023 to US\$102.7b in 2028.⁶ The present-day surgeon and trainee wonder not if, but how this development will alter the face of vascular training and education. The original scope of Technology Enhanced Learning (TEL) included e-Learning (eL), mobile learning and simulation-based training (Table 1).⁷ The newest recruit to this teaching armamentarium is AI. This editorial describes the distinct ways in which AI enabled VeL can augment eLearning extraordinarily.

Author for correspondence:

Nikolaos Patelis

Metropolitan General, 264 Mesogeion Avenue, Cholargos - Athens, Greece

E-mail: patelism@gmail.com

doi: 10.59037/djr4hv48

ISSN 2732-7175 / 2023 Hellenic Society of Vascular and Endovascular Surgery Published by Rotonda Publications All rights reserved. <https://www.heljves.com>

ADAPTIVE LEARNING

In past decades, one-size-fits-all teaching methods have been criticized for their inefficiency. AI enhanced VeL (AIVeL) proposes machine learning algorithms based on big data from past teaching activities, resulting in highly augmented adaptive learning. The adaptive process applies individual adjustments to the delivery of teaching content based on the ac-

Table 1: Definitions of technical terms & expressions used in text

Technical Term or Expression	Definitions	Abbreviation
Artificial Intelligence	Artificial intelligence is the simulation of human intelligence processes by machines, especially computer systems.	AI
Technology enhanced learning	Technology Enhanced Learning (TEL) is the implementation of technology into teaching methods to enhance the learning process	TEL
e-Learning	Learning conducted via electronic media, typically on the internet	eL
Neural networks	A computer system modelled on the human brain and nervous system	
Bayesian networks	A Bayesian network is a compact, flexible and interpretable representation of a joint probability distribution	
Support Vector Machine	A supervised learning algorithm used to solve classification and regression problems	SVM
Large Language Model	A type of artificial intelligence model that has been trained through deep learning algorithms to recognize, generate, translate, and/or summarize vast quantities of written human language and textual data.	LLM
Dr Google	The Internet when used to seek out medical advice, often by cyberchondriacs to scrutinize or challenge valid medical advice	
Aissance	The use of Artificial Intelligence to provide assistance in a setting of training and education	

ceptance that learners have diverse backgrounds, learning preferences and cognitive abilities. In the realm of conventional e-learning, such refinement is limited to the incorporation of a degree of 'program-and-platform-limited' reactivity into online educational activities. AI supported augmentation of eL matter can utilise AI algorithms to scrutinise learners' active and legacy interactions with the learning platform in real time. Leveraging this analysis, the system adjusts both the content and presentation of e-Learning modules to provide an individualised course targeting the desired learning outcomes (LOs). Assessing the actual grasp of pertinent knowledge or skills offered online can serve as a gauge for the effectiveness of e-Learning itself. e-Learning environments ought to be flexible enough to facilitate a range of productive activities, recognizing this acquisition as a constructive process that can manifest in diverse forms of learning engagement. Assistance from automated bots in an AI assisted eL environment would further bolster the learning experience. Examples of this vary in complexity; direct feedback to an incorrect response, incremental hints towards the correct response and technical tutoring to address targets of improvement. The application of AI analysis to composite learner responses and incorporation of these findings to derive a customised user algorithm that also subsumes influence from big data analysis will result in unparalleled adaptability of eL material. The powerful tailoring of both the quality and quantum of 'Assistance' made possible in this way will facilitate achievement of intended LOs by each individual user in the most efficient manner possible. Such AIVeL-based adaptive learning has immense potential to overcome the high dropout rates and low engagement previously described with e-Learning, further improving collective outcomes.

The results of adaptive AIVeL very significantly depend on the data harvest and analysis tool (e.g. neural networks, Bayesian networks or Support Vector Machines), as well as on the type of e-Learning used (e.g. micro-adaptive, macro-adaptive, linear). Each combination of an AI tool and an e-Learning type could alter significantly the output of the AIVeL system and either lead to positive or negative user experience.

LARGE LANGUAGE MODELS

Establishment of AIVeL as a training technology is likely, as with most new modalities, to take initial root in well-funded academic environments. Beyond this anticipated pilot phase, the ability of advanced AI language capabilities to offer VeL content to diverse groups in their native languages *on the fly*, without prior translation, will facilitate exponential scalability of AIVeL to the global market. A further benefit AIVeL could offer vascular education is the use of natural language algorithms for the grading and assessment of open text from content such as dissertations. Modern day AI models for such tasks are highly sensitive to plagiarism and can distinguish discrepancies of writing style to detect fraud.

At the same time, Large Language Models (LLMs) possess an ever-expanding capacity to generate text indistinguishable from human writing. The ability of LLMs to construct coherent and contextually appropriate content across various domains

will inevitably blur the lines between genuine human-generated work and AI-generated content in all fields including vascular surgery. The misrecognition of AI-authored e-Learning materials as human-created content has real potential to significantly exacerbate the already recognised "Dr Google" phenomenon, wherein users accept unaccredited medical material as *per se* correct. Unpublished research by *ChatAortaAI* has already identified variables that determine the results of LLMs - these include the particular language used, the available bid data in that language on a given subject and the phrasing of the 'input request' by the user.⁸ The AI-generated answer to a clinical question therefore depends on the language the user uses, the size of available big data in this language and finally the wording of the question.

It is important to appreciate the above practical challenges of accurate attribution of authorship posed by the advent of AIVeL. The unearthing of flawed or fraudulent AI-authored e-Learning materials will pose a further conundrum - if the best tool for ferreting out the 'bad apple' AIVeL output is, by definition, another AI algorithm, will this represent a situation of 'marking one's own homework'? These are fertile grounds for technical and ethical debate.

SIMULATION AND LIVE ASSISTANCE

The use of simulation in vascular surgery is well established and positive results have already been published.⁹ The use of AIVeL will substantially augment the level of detail and degree of finesse that can be enabled during a simulated 'pre-operative training run' on the specific patient's own anatomy in both open or endovascular settings. In addition, AI can enhance actual operative procedures by providing real-time guidance and assistance to vascular surgeons. An example of such an application would be AI mapping of advanced imaging and pre-operative road-mapping of the intended operative journey in a manner similar to the use of fusion registration of CT data during fenestrated EVARs. The ability of AI AI algorithms to identify imminent complications based on the extent of deviation of the actual operative steps from the preoperative 'intended path' within the context of individual anatomy and anomalies will enable use of such a technological safeguard in a way hitherto impossible during open surgery. AI augmented reality overlays during surgery can "Assist" accurate incisions, define approaches to tissue too scarred for the human eye to distinguish planes and flag up 'rogue bites' falling outside predefined parameters of adequacy during an anastomosis. The potential of such capabilities to reduce human error and enhance overall precision is indescribable. Additionally, AI algorithms can continuously analyze data from various sources (e.g. monitors, angiograms), predicting potential complications and providing immediate recommendations, ultimately improving patient outcomes and fostering a safer surgical environment. All the above could be of great significance to young vascular specialists as well as to trainees.

The potential of AIVeL comes into its own further still in the practical domain. Examples of such tutoring vary widely in complexity; a few would be direct feedback to an incorrect response, incremental hints towards the correct response and

technical tutoring to address targets of improvement in learning techniques. Such haptic and iterative feedback already exists in the endovascular simulator based domain.¹⁰ The superadded value conferred by AIVeL would fall into two broad categories. The first is the ability to present a multitude of potential 'technical' permutations derived from big data, filtered to the learner's choice. The user may choose to train on the most common patterns encountered in clinical practice, or to challenge themselves on the most complex presentations, as just two examples of preference. The second benefit is the unique capability of AI to provide analytical feedback in response to each training 'run' to a degree of finesse and depth that a simulator cannot accomplish and which most human trainers could not sustain consistently. Both these unique advantages would derive from AI interpretation of prior responses from the individual student and algorithms derived from big data analysis.

IMAGE GENERATORS

AI can create graphics and animations in vascular anatomy, vascular physiology and haemodynamics based on reality. The accuracy level achievable by such image generators is projected to improve exponentially over this decade. AIVeL depictions that are liberated from the inaccuracies that blight representations created *as a likeness* would provide a powerful tool for learning; they would also offer unparalleled potential for reversing the supply-demand imbalance in many healthcare sectors globally while - paradoxically - strengthening rather than weakening the credentialing of skill sets of 'new' operators. The favourable impact such training and practice models would proffer to patient safety profiles would help recruit support for AIVeL from regulatory and governance bodies.

CONCLUSION

The era of AIVeL appears to be upon us. There is much to deliberate about its potentials and pitfalls. It may be more pragmatic to engage actively with the practicalities and safeguards of implementing AIVeL, rather than permitting that process to progress without our involvement.

LITERATURE

- 1 Patelis N, Bisdas T, Jing Z, et al. Vascular e-Learning during the COVID-19 pandemic: the EL-COVID survey. *Ann Vasc Surg.* 2021.
- 2 Dickinson KJ, Caldwell KE, Graviss EA, et al. Assessing learner engagement with virtual educational events: Development of the Virtual In-Class Engagement Measure (VIEM). *Am J Surg.* 2021;222(6):1044-1049.
- 3 Fabiani MA, Gonzalez-Urquijo M, Cassagne G, et al. Thirty-three vascular residency programs among 13 countries joining forces to improve surgical education in times of COVID-19: A survey-based assessment. *Vascular.* 2022;30(1):146-150.
- 4 Jogerst K, Chou E, Tanious A, et al. Virtual Simulation of Intra-operative Decision-Making for Open Abdominal Aortic Aneurysm Repair: A Mixed Methods Analysis. *J Surg Educ.* 2022;79(4):1043-1054.
- 5 Patelis N, Rielo-Arias F, Bertoglio L, Matheiken SJ, Beard JD. Modular e-learning for a practical skill in vascular surgery. *Hellenic J Vasc Endovasc Surg.* 2020;2(1):31-34.
- 6 Artificial Intelligence in Healthcare market. 2023; https://www.marketsandmarkets.com/Market-Reports/artificial-intelligence-healthcare-market-54679303.html?gad_source=1&gclid=Cj0KCQjwy4KqBhD0ARIsAEbCt6hzTF-t2FehaJkNH8hidFifAeBbFkiqfAL_LISBYKLyqZxji3UPXb-caApF0EALw_wcB. Accessed 31/10/2023.
- 7 Patelis N, Matheiken SJ, Beard JD. The challenges of developing distance learning for surgeons. *Eur J Vasc Endovasc Surg.* 2015;49(3):237-238.
- 8 Think Tank Aorta. 2023; <https://www.linkedin.com/company/think-tank-aorta/>. Accessed 07/12/2024.
- 9 Haiser A, Aydin A, Kunduzi B, Ahmed K, Dasgupta P. A Systematic Review of Simulation-Based Training in Vascular Surgery. *J Surg Res.* 2022;279:409-419.
- 10 Hislop SJ, Hsu JH, Narins CR, et al. Simulator assessment of innate endovascular aptitude versus empirically correct performance. *J Vasc Surg.* 2006;43(1):47-55.

Total Endovascular Arch replacement for a Non-A, Non-B Aortic Dissection

Konstantinos Tzimkas-Dakis¹, Konstantinos Spanos¹, George Kouvelos¹, George Volakakis¹, Metaxia Bareka², Grigorios Giamouzis³, Eleni Arnaoutoglou², Miltiadis Matsagkas¹

¹ Department of Vascular Surgery, Faculty of Medicine, School of Health Sciences, University of Thessaly, Larissa, Greece

² Department of Anesthesiology, Faculty of Medicine, School of Health Sciences, University of Thessaly, Larissa, Greece

³ Department of Cardiology, Faculty of Medicine, School of Health Sciences, University of Thessaly, Larissa, Greece

Abstract:

Introduction: Branched Thoracic Endovascular Repair of the Aortic Arch (bTEVAR) is a feasible alternative to conventional open surgical repair or endovascular debranching techniques in unfit for open repair patients, allowing for complete endovascular repair of thoracic aortic pathologies involving the aortic arch, such as Non-A, Non-B dissections.¹

Case Report/Technique: We present the case of a 64-year-old male patient who was transferred to our department with an acute Non-A, Non-B aortic dissection, extending from the innominate artery to the aortic bifurcation. Following initial conservative management, the patient presented aortic diameter enlargement and was treated with a custom-made arch-branch device [Bolton Medical, Inc. (Terumo Aortic, US)], incorporating three directional branches for the innominate, left carotid and left subclavian artery, respectively. Postoperative 6-month follow-up shows nice graft deployment resulting in partial false lumen thrombosis with complete branch patency and no signs of type Ia endoleak or bird-peak formation.

Conclusion: Branched TEVAR appears to be feasible and safe as a treatment alternative for aortic pathologies involving the aortic arch, such as Non-A, Non-B dissections, while long-term postoperative surveillance is warranted.

INTRODUCTION

TEVAR has fundamentally changed the management of thoracic aortic syndromes, allowing for treatment of high-risk patients, unfit for traditional surgical repair.² Aortic lesions including descending thoracic aortic aneurysms, chronic Type B (Stanford Classification) dissections, intramural hematomas and penetrating aortic ulcers can be successfully treated with endovascular solutions, largely decreasing the high mortality and complication rates of open surgical repair, in both intact and emergent lesions.^{3,4}

Aortic pathologies involving the aortic arch require a more complex management, as standard TEVAR fails to provide a suffice proximal landing zone. Non-A, non-B aortic dissections, either limited to the aortic arch or evolving as a retrograde dissection with an entry point at the descending thoracic aorta institute complex lesions, unable to be treated with conventional TEVAR. Moreover, conventional open surgical repair as well as hybrid techniques including endovascular repair in addition to debranching of the aortic arch have been associat-

ed with increased morbidity and mortality, excluding high-risk patients.^{5,6} Fenestrated and branched (fTEVAR, bTEVAR) have been extensively used in the last decade as alternatives, allowing for proximal landing zone on the ascending aorta (Zone 0), while incorporating fenestrations or directional branches for implementation of the innominate, left carotid and left subclavian artery.⁷

CASE REPORT/TECHNIQUE

We present the case of a 64-year-old male patient, with no prior medical history or under any medication, who was transferred to our hospital following an acute non-A, non-B dissection. The patient presented with acute chest pain, radiating to his back, and uncontrolled systolic arterial pressure (~190mmHg). Initial management at a district hospital included aggressive arterial pressure and pulse management at a High Dependency Unit. The patient underwent a complete diagnostic work-up, including a Computed Tomography Angiography (CTA) of the aorta, detecting a non-A, non-B aortic dissection, alongside a descending thoracic aortic aneurysm (maximum diameter ~5.4cm). The dissection extended from proximally to Zone 1 and distally to Zone 10, with the initial entry point detected distally to the left subclavian artery (B₁₋₁₀), based on the reporting standards for type B aortic dissections.⁸ Following vital signs and clinical status stabilization, the patient was transferred to our department for further diagnostic and therapeutic management. During initial assessment, the patient was hemodynamically stable, with palpable upper and lower limb radial, brachial, femoral, popliteal, posterior tibial, and dorsalis pedis arteries. Follow-up CTA revealed no further retrograde or antegrade dissection. (Figure 1)

Author for correspondence:

Tzimkas-Dakis Konstantinos

Vascular Surgery Trainee, University of Thessaly, Mezourlo, 41110, Larissa, Greece

Tel: +302413501739

E-mail: kostasdakis1994@gmail.com

doi: 10.59037/djr4hv48

ISSN 2732-7175 / 2023 Hellenic Society of Vascular and Endovascular Surgery Published by Rotonda Publications
All rights reserved. <https://www.heljves.com>

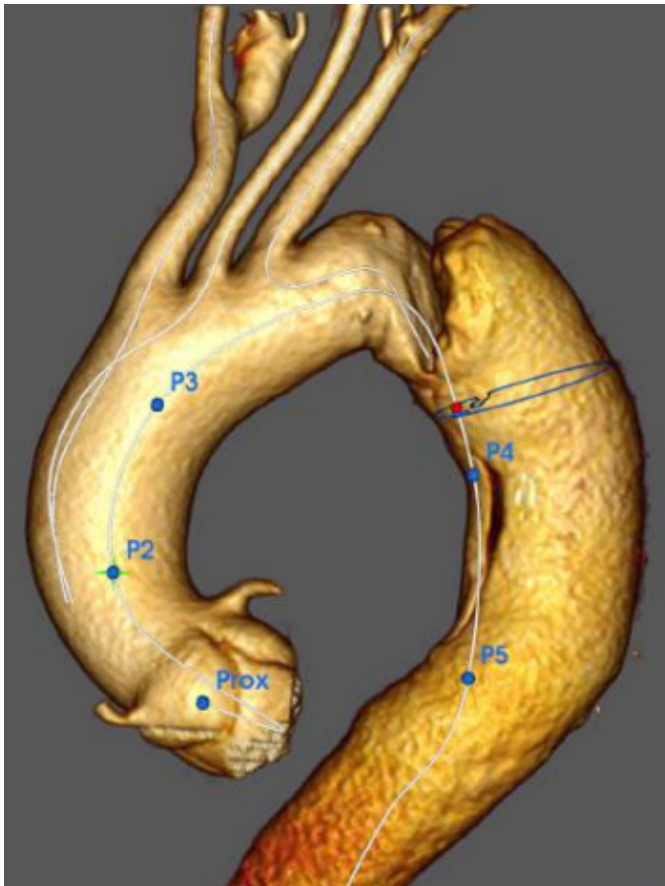


Figure 1. Preoperative aortic non-A, non-B dissection (3D Reconstruction)

Periaortic hematoma extended to the level of the innominate artery. (Figure 2) Reno-visceral arteries (celiac trunk, superior mesenteric artery, left renal artery) arose from the true aortic lumen besides the right renal artery which arose from the false lumen, with complete patency of all renovisceral vessels and no signs of dissection extension. Cardiothoracic evaluation was negative for open surgical repair. After thorough CTA examination and patient briefing, a total endovascular repair via branched TEVAR was decided, utilizing a custom-made device (CMD) [Bolton Medical, (Terumo Aortic, US)]. The patient was discharged with antihypertensive and beta-blockers medication until further notice following device manufacturing.

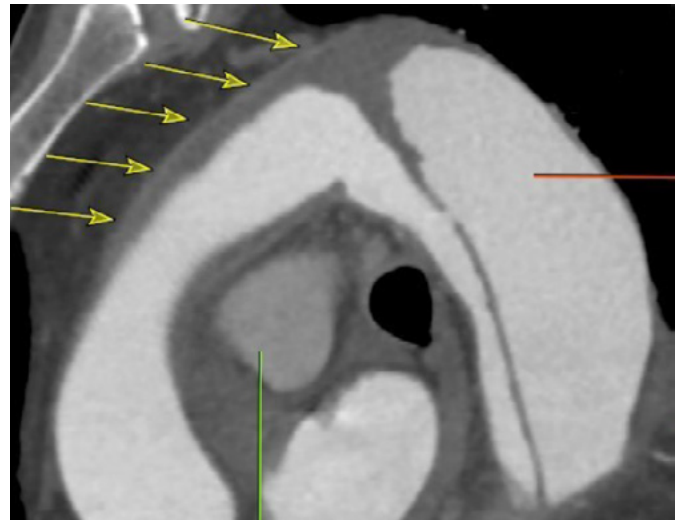


Figure 2. Hematoma extension to Zone 0.
Footnote: Yellow arrows depicting hematoma.

Branched Endograft Characteristics

A branched thoracic CMD endograft was designed and manufactured, including 3 branches, two for the incorporation of the innominate and left carotid (LCCA) and one retrograde branch for the left subclavian (LSA) artery. Proximal and distal endografts diameters were 46mm and 28mm, aiming for an approximately 25% proximal and 20% distal overlap at Zone 0 and 4, respectively. Total graft length was 270mm, while the implemented, inner directional branches were 12mm for the innominate and 10mm wide for the LCCA and LSA, respectively. All branches were 40mm in length, while the innominate and LCCA branches, cranially oriented, originated 60mm from the proximal end of the CMD and the LSA branch, caudally oriented, originating 125mm from the proximal end of the CMD. (Figure 3)

Additionally, a custom-made straight-tube endograft for bridging of the innominate artery was manufactured, with a 13-11mm, and 103mm proximal, distal diameter and length, respectively. Total manufacturing time from CMD design to delivery was 2 months. Bridging of the LCCA and the LSA was scheduled to be implemented through self-expanding and balloon-expandable covered stentgrafts (Viabahn and VBX, Gore & Associates, Newark, 555 Paper Mill Road, USA).

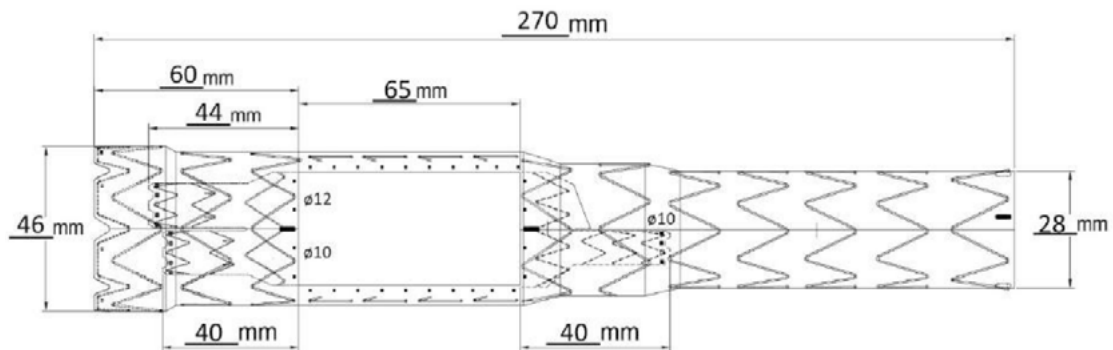


Figure 3. Custom-Made Arch Branch Device [Bolton Medical, (Terumo Aortic, US)]

Intraoperative Details/Procedure

Following general anesthesia induction, surgical cutdown of the common carotid arteries and the right common femoral artery was undertaken. Percutaneous vascular access of the right brachial artery was achieved for diagnostic angiography and the left common femoral vein for cardiac rapid ventricular pacing during device deployment, respectively. Following vascular access completion, per protocol 5000 IU of unfractionated heparin were administered for an ACT of >250 seconds, with 30-minute time interval ACT measurements and additional heparin infusions, when necessary. Prior to CMD introduction, carbon dioxide flushing of the device was thoroughly undertaken, for air embolization protection.⁹ A diagnostic angiography catheter was introduced via the right brachial artery, to the ascending aorta, later retracted during endograft deployment. The device was introduced, oriented, and deployed under rapid ventricular cardiac pacing of ~180 beats per minute (bpm) for approximately 30 seconds, eliminating aortic pulse pressure, for precise stentgraft deployment. Following successful device deployment, catheterization of the LCCA branch was initially achieved, and a VBX 11*59mm balloon-expandable covered stentgraft with a Viabahn 8*50mm self-expanding covered stentgraft were implanted, with a complete sealing of the branch. The innominate artery branch was later catheterized through the right CCA, introduction and deployment of the custom-made straight-tube 13-11*103mm endograft was successfully undertaken. Finally, through the right common femoral artery, the LSA branch and consequently the LSA were catheterized, a 11*100mm Viabahn self-expanding covered stentgraft was deployed successfully. Final angiogram confirmed precise CMD deployment from the coronary arteries, and complete branch patency, with no signs of endoleak. (Figure 4)

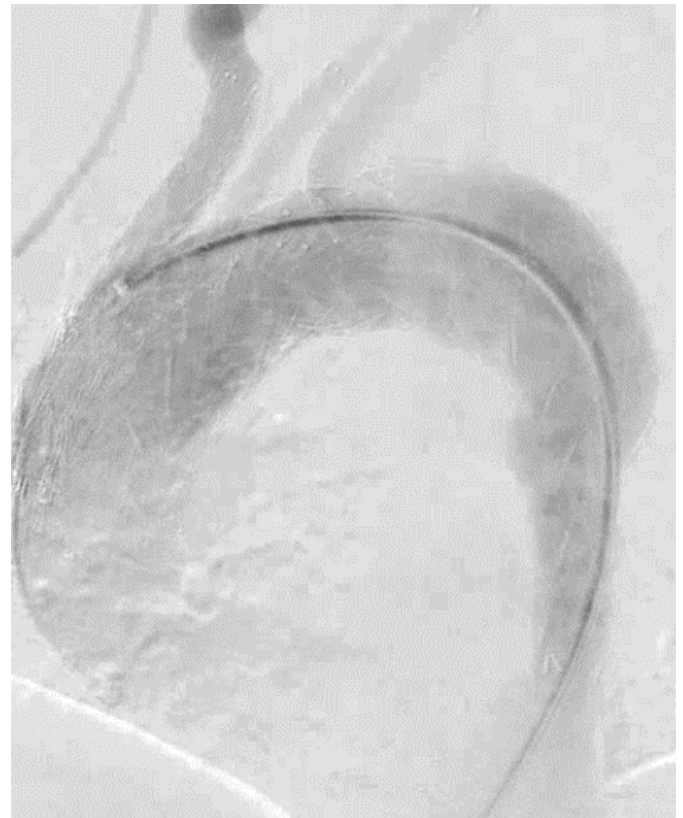

Figure 4. Intraoperative confirmation angiography

Following standard arterial suture closing, the patient was extubated with no signs of cerebral events and was transferred to the Vascular Surgery Ward under close monitoring. Total radiation time exposure and contrast media administration was 8.570 cGy/cm² and 120mls, respectively. No blood or blood products were transfused.

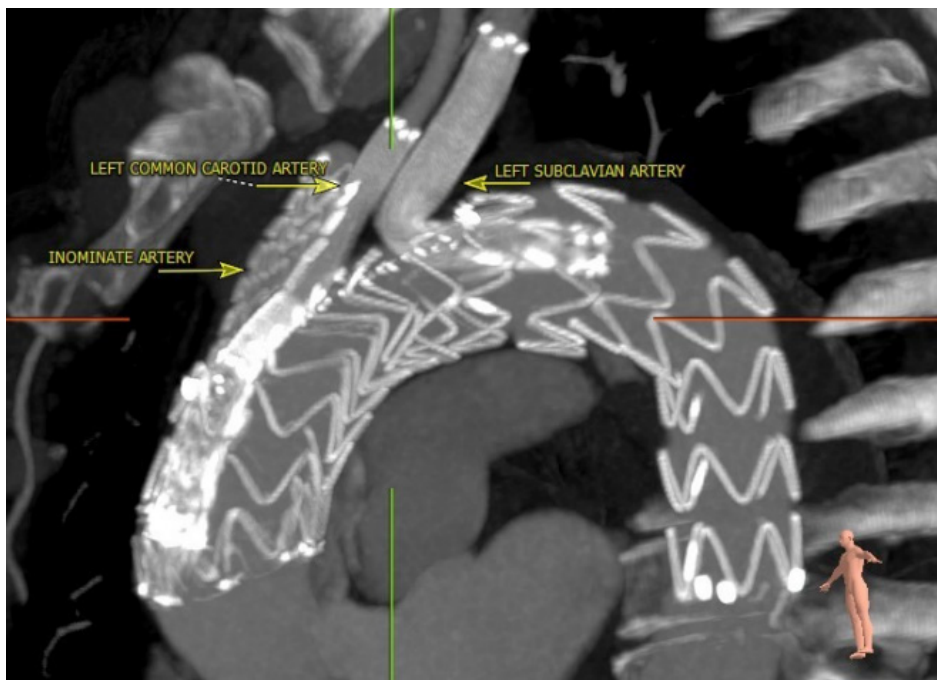

Figure 5. Postoperative 6-month arch-branch device configuration.

The patient received single antiplatelet therapy (Acetylsalicylic Acid, 100mg, OD) upon ward transfer, and dual antiplatelet therapy (Clopidogrel, 75mg OD) was administered on the 1st postoperative day. , and , The patient underwent a complete CTA scan the 2nd post-operative day, showing successful device implementation, total branch patency and no signs of endoleak or bird-peak formation. Postoperative recovery was uneventful and the patient was discharged on the 4th post-operative day. During follow-up, the patient has been well, with adequate blood-pressure and cardiac rhythm medication control. The 6-month postoperative CTA scan showed patency of all supra-aortic vessels and their branches resulting in partial false lumen thrombosis, due to distal entry points, with gradual aortic remodeling, with a maximum diameter of 5.2cm (Figure 5)

DISCUSSION

Non-A, non-B dissections are high-risk manifestations of TAD, often not amendable to standard TEVAR, nonetheless associated with intramural hematomas and retrograde dissections.¹⁰ Excluding cases requiring urgent open thoracic aortic repair through open conventional surgical total arch reconstruction or hybrid solutions involving arch debranching, complex endovascular repair of such lesions has proven to be feasible, with acceptable outcomes, including all-cause and aorta-related mortality, as well as complication and reintervention rates.⁷

Open surgical repair of thoracic aortic dissections involving the arch requires, total arch reconstruction with open sternotomy, cardiopulmonary bypass, and hypothermic circulatory arrest in most cases, and it is still recommended by guidelines as the gold standard. Such interventions have been traditionally associated to high morbidity and complication rates and prolonged ICU stay, rendering them restrictive for high-risk patients.³ Multidisciplinary evaluation is mandatory in all TAD cases, with complete patient vital sign, laboratory values and aorta CTA assessment, as open surgical repair could be the only available solution.

Branched and fenestrated thoracic aortic repair of TAD involving the arch and its branches requires diligent planning and sizing, and specific pre-, intra- and postoperative protocols for successful implementation in high-risk patients unfit for traditional repair.¹¹ Main entry point coverage with total endovascular incorporation of supra-aortic target vessels are essential parts for first management. Moreover, these technical characteristics are crucial for future aortic remodeling. In clinically stable patients or in chronic aortic dissection, with uncomplicated TAD, custom-made devices allow for design of “tailor-made” endografts, with no compromise regarding technical and clinical success. Fenestrated arch devices have been studied, albeit data is still scarce regarding branched devices.¹² Emergent endovascular approaches, including the hybrid procedures, chimney technique or in situ fenestrations, although extremely valuable, present high risk of gutter endoleaks, cerebral events and scarce long-term outcomes.^{13,14}

Careful preoperative CTA scan evaluation is of utmost importance prior to CMD design and production. Branched-TE-

VAR for arch lesions requires most of the time proximal seal at Zone 0. Misaligned deployment of an arch branch device could lead to catastrophic events, from coverage of the ostia of coronary arteries, to misalignment of branches or fenestrations in regard to the ostia of the supra-aortic vessels.¹¹ An important factor for successful deployment is the diameter of the ascending aorta. While data is limited, an oversize of approximately 20% on the proximal landing zone, in addition to most arch branch devices manufactured with a proximal stentgraft diameter of 45-50mm, restricts the use of arch branch devices in patients with ascending aorta diameter less than 40mm. Also, minimal tapering of the proximal landing zone is important in satisfactory proximal sealing of the endograft. Another important factor is aortic angulation at the sealing zone, with aortic angulations over 60° associated with higher risk of type Ia endoleaks.^{11,15}

Cerebral event protection has been and remains crucial during endovascular arch repair, especially when proximal seal occurs in Zone 0. Endovascular solutions involving the chimney technique, as well as hybrid arch reconstruction (applying the frozen elephant trunk technique) have been associated with risk of stroke over 10 and 16%, respectfully.^{16,17} Reports on total endovascular aortic arch repair suggest considerable stroke rates as high as 14%, further highlighting the need for vigilant measures of cerebral protection.¹⁸ Careful CMD flushing using carbon dioxide prior to introduction and deployment, rapid ventricular pacing, as well as meticulous sheath and wire flushing and exchange contribute towards successful subsequent CMD deployment and limitation of cerebral events.^{9,19} Data on short-term outcomes of branched total endovascular arch repair are associated with high technical success rates over 95% and no mortality during the initial 30-day postoperative period.⁷

CONCLUSION

Branched stentgraft device is a feasible procedure for totally endovascular repair of aortic lesions involving the arch. Longer follow up is needed to prove its durability and efficacy.

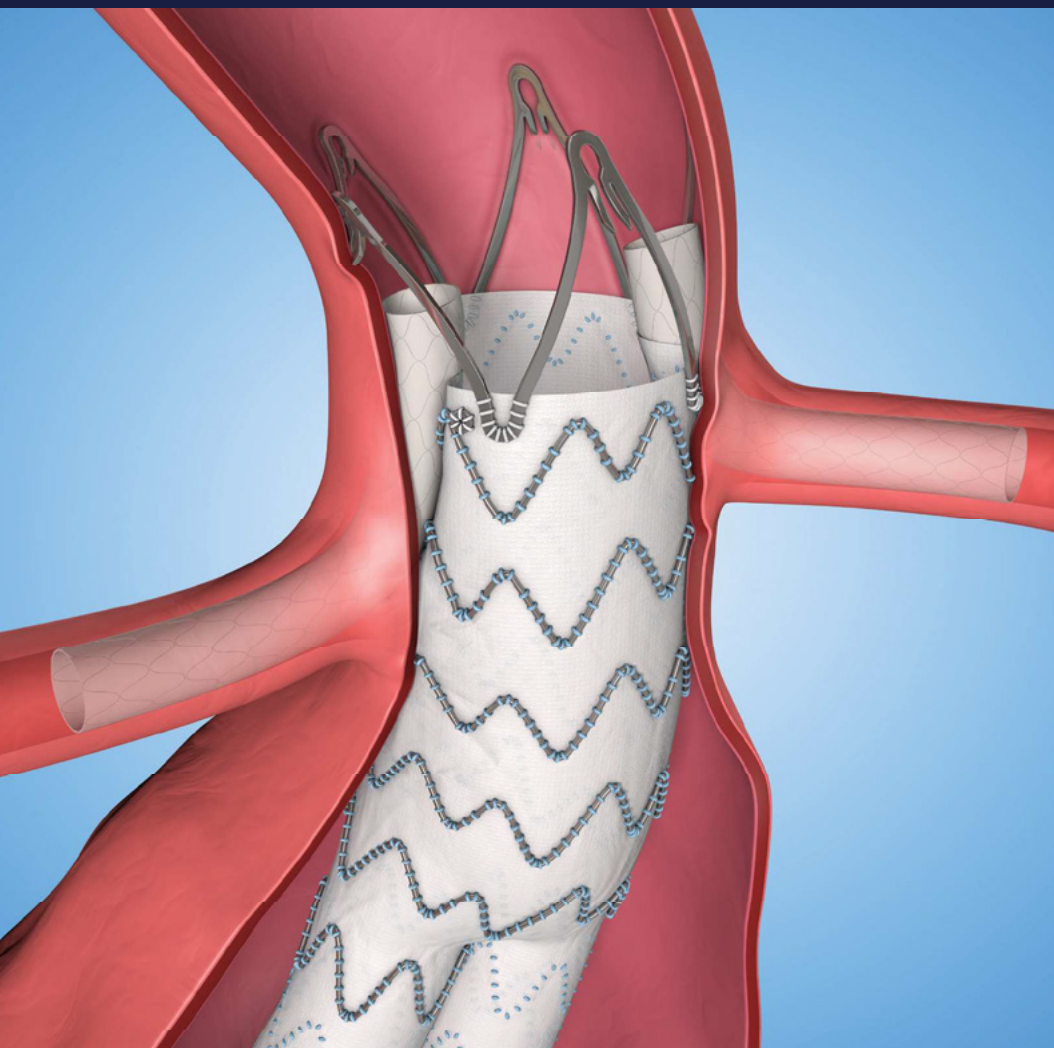
REFERENCES

- 1 Zhang L, Qingsheng L, Zhu H, Jing Z. Branch stent-grafting for endovascular repair of chronic aortic arch dissection. *J Thorac Cardiovasc Surg.* 2021;162(1):12-22.e1. DOI: 10.1016/j.jtcvs.2019.10.184.
- 2 Kamman AV, de Beaufort HWL, van Bogerijen GHW, Nauta FJH, Heijmen RH, Moll FL, et al. Contemporary Management Strategies for Chronic Type B Aortic Dissections: A Systematic Review. *PLoS One.* 2016, 4;11(5). DOI: 10.1371/journal.pone.0154930
- 3 Cheng D, Martin J, Shennib H, Dunning J, Muneretto C, Schueler S, et al. Endovascular aortic repair versus open surgical repair for descending thoracic aortic disease a systematic review and meta-analysis of comparative studies. *J Am Coll Cardiol.* 2010, 9;55(10):986-1001. DOI: 10.1016/j.jacc.2009.11.047.
- 4 Jonker FHW, Verhagen HJM, Lin PH, Heijmen RH, Tri-

- marchi S, Lee WA, et al. Open surgery versus endovascular repair of ruptured thoracic aortic aneurysm. *J Vasc Surg.* 2011;53(5):1210-6. DOI: 10.1016/j.jvs.2010.10.135.
- 5 Konstantinou N, Debus ES, Vermeulen CFW, Wipper S, Diener H, Larena-Avellandea A, et al. Cervical Debranching in the Endovascular Era: A Single Center Experience. *Eur J Vasc Endovasc Surg.* 2019;58(1):34-40. DOI: 10.1016/j.ejvs.2018.12.010.
 - 6 Matsagkas M, Kyrou I, Kouvelos G, Arnaoutoglou, Papakostas JC, Katsouras CS, et al. Follow-up papers - aortic and aneurismal stenting of the descending thoracic aorta: A six-year single-center experience. *Interact Cardiovasc Thorac Surg.* 2011;12(5): 789-93. DOI: 10.1510/icvts.2010.262584.
 - 7 Tsilimparis N, Debus ES, von Kodolitsch Y, Wipper S, Rohlfss F, Detter C, et al. Branched versus fenestrated endografts for endovascular repair of aortic arch lesions. *J Vasc Surg.* 2016;64(3):592-9. DOI: 10.1016/j.jvs.2016.03.410.
 - 8 Lombardi JV, Hughes GC, Appoo JJ, Bavaria JE, Beck AW, Cambria RP, et al. Society for Vascular Surgery (SVS) and Society of Thoracic Surgeons (STS) reporting standards for type B aortic dissections. *J Vasc Surg.* 2020;71(3):723-747. DOI: 10.1016/j.jvs.2019.11.013.
 - 9 Kölbel T, Rohlfss F, Wipper S, Carpenter SW, Debus ES, Tsilimparis N. Carbon Dioxide Flushing Technique to Prevent Cerebral Arterial Embolism and Stroke During TEVAR. *J Endovasc Ther.* 2016;23(2):393-5. DOI: 10.1177/1526602816633705.
 - 10 Howard C, Ponnappalli A, Shaikh S, Idhress M, Bashir M. Non-A non-B aortic dissection: A literature review. *J Card Surg.* 2021;36(5):1806-1813. DOI: 10.1111/jocs.15349.
 - 11 Spanos K, Panuccio G, Rohlfss F, Heidemann F, Tsilimparis N, Kölbel T. Technical Aspects of Branched Thoracic Arch Graft Implantation of Aortic Arch Pathologies. *J Endovasc Ther.* 2020;27(5):792-800. DOI: 10.1177/1526602820925443
 - 12 Melo RGE, Prendes CE, Khanafer A, Wanhainen A, Mani K, Rouhani G, et al. Common designs of Custom-Made Fenestrated Arch Devices and Applicability of an Off-the-Shelf Design. *J Endovasc Ther.* 2023;9. DOI: 10.1177/15266028231179593.
 - 13 Zhao Y, Fenk J, Yan X, Zhu G, Zhou J, Li Z, et al. Outcomes of the Chimney Technique for Endovascular Repair of Aortic Dissection Involving the Arch Branches. *Ann Vasc Surg.* 2019;58(238-247). DOI: 10.1016/j.avsg.2018.10.041.
 - 14 Glorion M, Coscas R, McWilliams RG, Javerliat I, Brissonnier OG, Coggia M. A comprehensive Review of In Situ Fenestration of Aortic Endografts. *Eur J Vasc Endovasc Surg.* 2016;52(6):787-800. DOI: 10.1016/j.ejvs.2016.10.001
 - 15 Rudarakanchana N, Jenkins MP. HP. Hbrid and total endovascular repair of the aortic arch. *Br J Surg.* 2018;105(4):315-327. DOI: 10.1002/bjs.10713.
 - 16 Berger T, Kreibich M, Mueller F, Breurer-Kellner L, Rylski B, Kondov H, et al. Risk factors for stroke after total aortic arch replacement using the frozen elephant trunk technique. *Interact Cardiovasc Thorac Surg.* 2022;34(5):865-871. DOI: 10.1093/icvts/ivac013.
 - 17 Mangialardi N, Serrao E, Kasemi H, Alberti V, Fazzini S, Ronchey S. Chimney technique for aortic arch pathologies: an 11-year single-center experience. *J Endovasc Ther.* 2014;21(2)312-23. DOI: 10.1583/13-4526MR.1
 - 18 Bash AM, Moore RD, Rommens KL, Herget EJ, McClure RS. A Systematic Review of Total Endovascular Aortic Arch Repair: A Promising Technology. *Can J Cardiol.* 2023;39(1):39-56.
 - 19 Joseph G, Thomson VS, Kota A. Rapid Ventricular Pacing During Endograft Deployment in the Arch and Ascending Aorta: A Simple, Reliable, and Sage Technique Using a Stabilizing Buddy Wire System. *Eur J Vasc Endovasc Surg.* 2021;2(61):338-339. DOI: 10.1016/j.ejvs.2020.10.019

LEADING BY EXAMPLE

The first stent graft approved
for use in ChEVAR



Endurant™ II/IIa
AAA Stent Graft System

Medtronic is the first and only company to provide a standardized, off-the-shelf alternative for juxtarenal with short neck aneurysm patients.

- Indicated for patients with ≥ 2 mm neck length and $\leq 60^\circ$ infrarenal angle

medtronic.com/aortic

ChEVAR Indication not approved globally. Check local regulatory status.
For complete product information visit www.medtronic.com/manuals. Consult instructions for use at this website. Manuals can be viewed using a current version of any major internet browser.
For best results, use Adobe Acrobat® Reader with the browser.

UC201703254 EE © Medtronic 2016. All Rights Reserved.

Medtronic
Further, Together



PP-XAR-GR-0168-1
03.2020



Κάτοχος της άδειας κυκλοφορίας:
Bayer AG, 51368 Leverkusen, Γερμανία.
Τοπικός αντιπρόσωπος του κατόχου άδειας
κυκλοφορίας στην Ελλάδα: Bayer Ελλάς
ABEE, Σωρού 18-20, 151 25 Μαρούσι.
Τοπικός αντιπρόσωπος του κατόχου άδειας
κυκλοφορίας στην Κύπρο: Novagem Ltd,
Τηλ: 00357 22483858.
Τμήμα Επιστημονικής Ενημέρωσης
Τηλ: +30 210 6187742, Fax: +30 210 6187522
Email: medinfo.gr.cy@bayer.com

Εταιρεία συμπρώθησης



ELPEN Α.Ε. ΦΑΡΜΑΚΕΥΤΙΚΗ ΒΙΟΜΗΧΑΝΙΑ
Λεωφ. Μαραθώνος 95, 190 09 Πικέρμι Αττικής,
Τηλ: 210 6039326 - 9, Fax: 210 6039300
ΓΡΑΦΕΙΑ ΕΠΙΣΤΗΜΟΝΙΚΗΣ ΕΝΗΜΕΡΩΣΗΣ
Σεβαστείας 11, 115 28 Αθήνα,
Τηλ: 210 7488711, Fax: 210 7488731
Εθν. Αντιστάσεως 114, 551 34 Θεσσαλονίκη,
Τηλ: 2310 459920 - 1, Fax: 2310 459269



Xarelto[®]
rivaroxaban

Βοηθήστε να γίνουν τα φάρμακα πιο ασφαλή και
Αναφέρετε
ΟΛΕΣ τις ανεπιθύμητες ενέργειες για
ΟΛΑ τα φάρμακα
Συμπληρώνοντας την «ΚΙΤΡΙΝΗ ΚΑΡΤΑ»

Emerging evidence in the diagnosis and management of carotid near-occlusion

Constantine N. Antonopoulos MD¹, Georgios Tzavellas MD², Vasileios Bouris, MD², Efthymios D. Avgerinos MD², Christos D. Liapis, MD²

¹ Department of Vascular Surgery, National and Kapodistrian University of Athens, Attikon University Hospital, Athens, Greece

² Department of Vascular & Endovascular Surgery, Athens Medical Center, Athens, Greece

Abstract:

Carotid near-occlusion (CNO) is a form of carotid disease with severe internal carotid artery (ICA) stenosis and a significantly reduced lumen diameter distal to the stenosis. CNO is characterised as either having distal complete, thread-like, lumen collapse or not and is referred to as CNO with or without full collapse, respectively. Diagnosis has been traditionally performed with Digital Subtraction Angiography (DSA) using four angiographic criteria. However, the delayed phase of multiphase Computed Tomography Angiography (CTA) has largely replaced DSA and it is currently the CNO imaging of choice. Ultrasonography may also help in detecting low flow velocity. CNO has been under-reported in clinical practice and its optimal treatment is still debated, while contradicting evidence has been reported concerning the association between CNO and significant risk of stroke. The most recent 2023 ESVS guidelines suggested that intervention is not recommended for symptomatic CNO patients, unless as part of a randomised controlled trial, while for recurrent symptoms, intervention may be considered only after multidisciplinary team review. However, this recommendation was mainly based on a post-hoc analysis of pooled data from NASCET and ECST trials, performed in the 1990s. Recent studies have also provided various results, which are partly attributed to the lack of clear CNO definition, heterogeneous cohorts and inadequate discrimination between CNO with and without full collapse. Our review presents an overview of the current evidence for the diagnosis and treatment of patients with CNO.

Keywords: carotid, near-occlusion, diagnosis, management

INTRODUCTION

Carotid near-occlusion (CNO) is part of the spectrum of severe carotid stenosis, where the internal carotid artery (ICA) distal to the stenosis appears diminutive, in contrast to more common ICA stenosis, which does not result in diameter decrease of the distal ICA¹. CNO is characterized as either having complete distal, thread-like, lumen collapse or not and is referred as CNO with or without full collapse, respectively². CNO was initially reported by Lippman et al. in 1970³ and has since been reported using a variety of nomenclature.

Despite being recognized as rare, CNO is more prevalent among symptomatic patients with $\geq 50\%$ ICA stenosis⁴. The European Carotid Surgery Trial (ECST) and the North American Symptomatic Endarterectomy Trial (NASCET) post-hoc analyses demonstrated that individuals with symptomatic CNO

would not benefit from surgery and that their risk of recurrent stroke might be lower than that of patients with severe ICA without near-occlusion. However, these trials were conducted in the 1990s and it is debatable whether their results are still valid today. Although recent evidence has linked symptomatic CNO to an elevated risk of ipsilateral hemisphere stroke, large prospective studies to ascertain the exact risk of recurrent stroke among these patients are currently lacking². Even the most recent prospective Randomised Clinical Trials (RCTs), such as the International Carotid Stenting Study (ICSS) and the Carotid Revascularization Endarterectomy vs Stenting Trial (CREST) did not recruit patients with symptomatic CNO⁴. As a result, there is lack of evidence to support or reject revascularization in patients with CNO, and the optimal management is still debatable. Our study aimed to perform an overview of the current evidence for the diagnosis and treatment of patients with CNO.

Author for correspondence:

Professor Christos D. Liapis, MD

Department of Vascular and Endovascular Surgery, Athens Medical Center, Athens, Greece, 56 Kifisias Ave. & Delfon Str, 15125, Marousis, Athens, Greece
Tel: +30 2106862637

E-mail: liapis@med.uoa.gr

doi: 10.59037/ahmtvw58

ISSN 2732-7175 / 2023 Hellenic Society of Vascular and Endovascular Surgery Published by Rotonda Publications
All rights reserved. <https://www.heljves.com>

OTHER TERMS FOR CNO

Various terms have been used to describe CNO, such as near total occlusion, pseudo-occlusion, string sign, slim sign, critical stenosis, small or narrow distal ICA, pre-occlusive stenosis, subtotal stenosis, subtotal occlusion, functional occlusion, sub-occlusion, 99% stenosis, hairline residual lumen and incomplete occlusion⁵. Due to similarities with other ICA pathologies causing distal lumen collapse, some authors proposed the term “atheromatous pseudo-occlusion” to separate CNO

from other non-atherosclerotic entities, such as dissection, hypoplasia or post-radiation lesions⁶. In line with this, the use of “string sign” should be also discouraged, as it was originally defined for describing dissection⁷.

EPIDEMIOLOGY AND NATURAL HISTORY

CNO has been reported with a prevalence of less than 10% among patients with significant ICA stenosis⁸ and approximately 3% among symptomatic patients². A total of 40% of these patients will present with ICA occlusion within 12 months. More specifically, progression from discovery to total occlusion with best medical therapy (BMT) has been estimated at 16 per 100 person-years⁹. However, our knowledge of exact CNO's natural history is limited. Previous studies described rates of progression to occlusion between 26-37% per year¹⁰. In a recent study, almost a third of patients with CNO progressed to complete occlusion at 24 months follow-up. The proportion of symptomatic progression to complete occlusion was 17.5% of the patients who presented with ipsilateral symptoms¹⁰. This can be attributed to collateral brain network and effective autoregulation of the cerebral circulation that adapts for the chronically diminished blood flow¹⁰.

PATHOPHYSIOLOGY OF STROKE IN CNO PATIENTS

Although not clearly investigated, the pathophysiological mechanism of stroke among CNO patients could be attributed to ICA progression to occlusion. However, a recent study failed to identify fully collapsed symptomatic near-occlusions which progressed to occlusion⁷. Hemodynamic and embolic mechanisms have also been investigated. Progression of ICA near occlusion to complete occlusion may lead to decreased perfusion of the ipsilateral hemisphere blood supply from the ICA, depending its perfusion from collaterals, which in turn may stimulate blood stagnation, increased risk of thrombus formation and eventually to embolization to intracranial collaterals¹¹. Interestingly, some near-occlusions can represent recanalized thrombotic occlusions with risk for embolic events.

THE CORRELATION OF HIGH RISK OF ISCHEMIC STROKE AMONG CNO PATIENTS IS STILL UNDER INVESTIGATION

Contradicting evidence has been reported concerning the association between CNO and significant risk of stroke. Since there was a comparatively low long-term risk of stroke in the medical arm, carotid endarterectomy (CEA) did not significantly improve outcomes among patients with CNO without full collapse in the NASCET and ECST trials. While these trials reported a relatively low risk of recurrent stroke in the medical arm, a recent study indicated a significant risk of recurrence across patients with CNO¹². A possible explanation is the disparity in timing of intervention. These trials frequently included near-occlusion patients with a significant delay (> 4 weeks) after the last incident. Another explanation is that the higher risk in recent studies may be due to risk difference between CNOs with and without full collapse. The authors noted that a large number of high-risk CNO patients with full collapse were initially misdiagnosed as occlusions in routine practice imaging, but were correctly identified by the experts. In addition,

a large number of the high-risk near-occlusions, which were later deemed technically untreatable, had a significant risk of stroke when intervention was attempted¹².

In line with the above, another recent study found increased risk of recurrent ipsilateral ischemic stroke in the early days following the presenting episode in CNO patients. The stroke rate among patients with CNO with full collapse was 18%, whereas the respective risk in patients without full collapse was low¹. We believe that the reason of the difference in the rate of stroke recurrence among the various studies, is the unclear distinction between outcomes of CNO patients with and without full collapse. This is independent of the progression to complete occlusion, as also pointed by a recent study⁷.

Similarly, other studies showed increased risk of recurrent stroke with a cumulative annual incidence of ipsilateral ischemic stroke of 14% and ipsilateral transient ischemic attack (TIA) of 24% in the group of patients who received medical treatment⁴. This was also confirmed by our previous systematic review on the topic. We found that BMT was presented with almost three-fold higher stroke IR per 100 person-years compared to carotid endarterectomy or stenting¹³. However, it should be highlighted that the suggested BMT is improved significantly over the past 20 years, thus we cannot exclude lower stroke risk in the future studies' medical treatment arms.

DIAGNOSIS

CNO with full collapse can be recognised as a thread-like appearance of distal ICA, which responds to reduction in flow⁵, whereas less severe flow reduction leads to a “normal-appearing” but small distal artery (near-occlusion without full collapse) (1). Although seems clear, CNO can be misdiagnosed to conventional stenosis with suboptimal imaging and interpretation⁵.

Digital Subtraction Angiography (DSA) is the gold standard

DSA has been the gold standard for the diagnosis of CNO. Four angiographic criteria were suggested by Fox et al.¹⁴: (I) reduction in ICA diameter compared with the ipsilateral external carotid artery (ECA), (II) obviously reduced diameter of the ICA compared with the opposite ICA, (III) intracranial collaterals seen as a cross-filling of contralateral vessels or ipsilateral contrast dilution and (IV) delayed cranial arrival of ICA contrast compared with that of the ECA. Two of the 4 criteria are required for diagnosis. However, the clinician should not overestimate CNO without full collapse, because the relatively small size of a distal ICA with a larger contralateral ICA can be an anatomic variation. Other variations that should be noted is diversity in ICA size depending on circle of Willis variations, or a single ICA supplying both anterior cerebral arteries^{5,11}. It is also important to differentiate CNO from long distal ICA tapering of dissection, as the later do not show a prominent ICA bulb stenosis or true ICA hypoplasia which shows a tiny bony carotid canal^{5,11}. Differentiating CNO from occlusion is also very important. Delayed angiography may be useful to detect delayed contrast through a severely collapsed artery.

Differentiating CNO with and without full collapse is also of paramount importance and it is based mainly on the “thread-like” distal ICA lumen^{5,11}.

Diagnosis with ultrasonography

Ultrasound can be also important for the diagnosis of CNO. The main characteristic is the presence or absence of blood flow. CNO with full collapse can be seen as a very tight stenosis with a minimal flow channel, slow flow velocities and a grossly pathologic flow profile or dampened, pseudo-venous flow with low pulsatility. The best stenosis PSV threshold for “low velocity” is likely slightly above 125 cm/s. However, when it comes to CNO without full collapse, differential diagnosis from conventional high grade ICA stenosis is difficult, as both have high flow velocities. In that case, Power Doppler, contrast-enhanced sonography and/or transoral sonography to also assess distal artery patency at the level of the pharynx may be useful adjuncts^{5,11,15}. However, given the difficulty in diagnosis CNO with ultrasound in the every-day practice, its diagnostic accuracy is still limited.

Diagnosis with Computed Tomography Angiography (CTA)

CTA is probably the most important and useful tool for the diagnosis of CNO. Bartlett et. al.¹⁶ proposed CTA-specific diameter-measurement criteria for the diagnosis of CNO: 1) stenosis diameter of ≤ 1.3 mm, 2) ipsilateral distal ICA diameter of ≤ 3.5 mm, 3) ipsilateral distal ICA/contralateral distal ICA ratio of ≤ 0.87 and 4) ipsilateral distal ICA/ipsilateral ECA of ≤ 1.27 . Interestingly, a recent validation study included patients with CNO, severe ICA stenosis and ICA occlusion and compared the diagnostic accuracy of CTA with DSA among many studies¹⁷. The most accurate criteria were i) distal ICA diameter less than or equal to the ipsilateral ECA, ii) ICA to ECA comparison of diameter reduction and iii) the ratio of the distal internal carotid artery (ICA) diameter to that of the contralateral distal ICA ≤ 0.87 ¹⁷.

Magnetic Resonance Angiography (MRA) for the diagnosis of CNO

MRA is not very popular for the diagnosis of CNO. Slow-flow signal is below the visibility threshold in TOF MRA, while the flow gap is almost identical in CNO with and without full collapse. However, when found, segmental flow gaps may suggest vessel patency, because occlusions are more likely to show full length signal absence^{5,11}.

Recommendation for diagnosis of CNO

CTA is suggested for current CNO diagnosis. Delayed phase of multiphase CTA imaging is mandatory, mainly as a routine postcontrast head CTA looking for a late, slow-flowing collapsed ICA lumen at the skull base or carotid canal. Other relative measurements necessitate a comparison, but this comparison may occasionally be deceptive since, for example, bilateral CNO affects ICA ratio and ECA sizes. Ultrasonography, although not definite, may also help in detecting low flow velocity.

PRACTICE GUIDELINES FOR THE MANAGEMENT OF CNO

Recent guidelines have commented for the management of patients with CNO. Among them, the 2017 Clinical Practice Guidelines of the European Society for Vascular Surgery (ESVS)¹⁸, suggested that “*carotid endarterectomy or carotid stenting are not recommended in symptomatic patients with a chronic internal carotid near-occlusion, unless associated with recurrent ipsilateral symptoms (despite optimal medical therapy) and following multidisciplinary team review*”. Moreover, the 2021 Society for Vascular Surgery (SVS) Guidelines did not discriminate treatment between high grade and CNO patients¹⁹. Even recently, the 2023 ESVS guidelines stated that “*for symptomatic patients with carotid near occlusion and distal vessel collapse, carotid endarterectomy and carotid stenting are not recommended, unless as part of a randomised controlled trial*” and that “*for patients with carotid near occlusion and distal vessel collapse with recurrent carotid territory symptoms (despite best medical therapy), carotid endarterectomy or carotid artery stenting may be considered only after multidisciplinary team review*”²⁰.

CRITIQUE ON THE RECENT PRACTICE GUIDELINES FOR THE MANAGEMENT OF CNO

It is evident that recent guidelines suggested a rather conservative treatment of patients with CNO. However, this recommendation is mainly based on a post hoc reanalysis of pooled data from NASCET and ECST. This data, although coming from RCTs, are probably outdated for the following reasons. BMT included only aspirin therapy in varying doses and antihypertensive treatment, whereas now medical therapy has improved significantly. An intention-to-treat analysis was used in NASCET, which might have underestimated the benefit of CEA in CNO patients, due to the high crossover rate during follow-up in the BMT group. The lower stroke risk in the BMT group may have been attributed to the lower prevalence of some risk factors, such as older age, diabetes, ischaemic heart disease and hyperlipidaemia in ECST. Timing is also very important. Only 35-45% of the patients were randomized within the first month, in which the benefit of intervention is the largest. Moreover, it is likely that large number of patients with chronic CNO were also included in these trials, and such patients may benefit more from BMT, compared to the patients with an acute CNO⁸. What is more, 94% of CNO patients included in these trial did not have full collapse²¹. Far less, patients with CNO were excluded from recent RCTs such as the CREST and the ICSS. It is therefore important to update our current knowledge with new prospective RCTs, incorporating patients with CNO with and without full collapse.

RECENT EVIDENCE AND CONTROVERSIES

Despite the fact that recent guidelines pointed to BMT for patients with CNO, current non-randomized studies are presenting with various results. A recent meta-analysis showed that BMT was not superior to CEA or CAS with respect to 30-day or 1-year stroke or death prevention⁸. The authors found that the risk of stroke or death within 30 days after intervention was very low (1.8% after CEA and 2.2% after CAS), that the

BMT group was not optimized in terms of antiplatelet, statin and antihypertensive treatment and that it is still room for improvement of BMT in future studies.

A recent multicentre registry study showed that the risk of early recurrent stroke may be higher in BMT with symptomatic CNO⁴. This, along with the good results with CAS or CEA in CNO patients^{22,23} might indicate that BMT is not a better choice, compared to intervention. A study by Antonopoulos et al.⁹ also found low stroke rates after intervention, at 1.52% after CEA and 1.80% after CAS, compared to 8.39% after BMT. Terada et al.²⁴ also found good results after CAS, indicating that it may be a good alternative to CEA, given its low risk, high success rate and feasibility. However, it should be highlighted that CAS is best to be performed by an experienced team and with minimum wire manipulations⁹.

POINTS OF INTEREST WHEN ASSESSING CNO

Although it seems paradoxical, there is still discrepancy between guidelines and many recent studies concerning the optimal management of patients with CNO. A key point when assessing CNO is the lumen full collapse. A study has found that the 90-day recurrent stroke risk could reach up to 43% in patients with symptomatic CNO with full collapse and 0% for patients without full collapse⁷. Unfortunately, many studies have not separated these two entities (with or without full collapse) as it seems that the possibility of near occlusion without full collapse has not been fully acknowledged⁹.

Another interesting point relies on the technique itself. The use of shunt during CEA for CNO is an important factor. The distal ICA may be too thin for proper shunt insertion and it should be probably avoided. In that case, systolic blood pressure should be maintained at increased levels to provide better collateral perfusion. In some other cases, severe concentric or eccentric calcification might hamper stent implantation during CAS and this should be included in the preoperative planning to avoid unnecessary embolic risk².

An important issue is also the post-operative management of CNO patients. As pre-operative intracranial perfusion is especially poor among those patients, reperfusion injury is more likely after a successful blood flow restoration to the brain, compared to conventional high grade ICA stenosis. Monitoring with strict blood pressure control is mandatory post-operatively in order to prevent brain oedema and possible intracerebral hemorrhage².

CONCLUSIONS

CNO is a frequently overlooked and easily misdiagnosed condition and its treatment strategy still remains debatable. This is partly attributed to the lack of a clear CNO definition, which may have led to heterogeneous cohorts and results among the various reports. Another relevant unsolved issue is the proper identification of CNO, as there is no easily applicable diagnostic modality with high diagnostic accuracy. Moreover, the exact mechanism, hemodynamic, embolic, by which the presence of full collapse may lead to an increased risk for ipsilateral stroke is still not well understood. The potential bene-

fit of intervention in CNO patients is also not clearly depicted from the literature. As a result, identification of high-risk CNO patients that may require intervention is of paramount importance. Future RCTs should be designed to properly address these issues²⁵.

REFERENCES

- 1 Johansson E, Gu T, Fox AJ. Defining carotid near-occlusion with full collapse: a pooled analysis. *Neuroradiology*. 2022;64(1):59-67.
- 2 Zhang J, Chen J, Xu X, Sun M, Chen S, Liu P, et al. Carotid Endarterectomy for the Treatment of Carotid Near-Occlusion With Recurrent Symptoms. *Front Neurol*. 2022;13:765795.
- 3 Lippman HH, Sundt TM, Jr., Holman CB. The poststenotic carotid slim sign: spurious internal carotid hypoplasia. *Mayo Clin Proc*. 1970;45(11):762-7.
- 4 Garcia-Pastor A, Gil-Nunez A, Ramirez-Moreno JM, Gonzalez-Nafria N, Tejada J, Moniche F, et al. Early risk of recurrent stroke in patients with symptomatic carotid near-occlusion: Results from CAOS, a multicenter registry study. *Int J Stroke*. 2017;12(7):713-9.
- 5 Johansson E, Fox AJ. Carotid Near-Occlusion: A Comprehensive Review, Part 1--Definition, Terminology, and Diagnosis. *AJNR Am J Neuroradiol*. 2016;37(1):2-10.
- 6 Xue S, Tang X, Zhao G, Tang H, Cai L, Fu W, et al. A Systematic Review and Updated Metaanalysis for Carotid Near-Occlusion. *Ann Vasc Surg*. 2020;66:636-45 e3.
- 7 Johansson E, Ohman K, Wester P. Symptomatic carotid near-occlusion with full collapse might cause a very high risk of stroke. *J Intern Med*. 2015;277(5):615-23.
- 8 Meershoek AJA, de Vries EE, Veen D, den Ruijter HM, de Borst GJ, group Ns. Meta-analysis of the outcomes of treatment of internal carotid artery near occlusion. *Br J Surg*. 2019;106(6):665-71.
- 9 Antonopoulos CN, Giosdekos A, Mylonas SN, Liapis CD. Management of internal carotid artery near-occlusion: the need for updated evidence. *Ann Transl Med*. 2020;8(19):1263.
- 10 Garcia-Pastor A, Gil-Nunez A, Ramirez-Moreno JM, Gonzalez-Nafria N, Tejada J, Moniche F, et al. Progression of carotid near-occlusion to complete occlusion: related factors and clinical implications. *J Neurointerv Surg*. 2020;12(12):1180-5.
- 11 Johansson E, Fox AJ. Carotid Near-Occlusion: A Comprehensive Review, Part 2--Prognosis and Treatment, Pathophysiology, Confusions, and Areas for Improvement. *AJNR Am J Neuroradiol*. 2016;37(2):200-4.
- 12 Gu T, Aviv RI, Fox AJ, Johansson E. Symptomatic carotid near-occlusion causes a high risk of recurrent ipsilateral ischemic stroke. *J Neurol*. 2020;267(2):522-30.
- 13 Mylonas SN, Antonopoulos CN, Moulakakis KG, Kakisis JD, Liapis CD. Management of Patients with Internal Carotid Artery Near-total Occlusion: An Updated Meta-analysis.

- Ann Vasc Surg. 2015;29(8):1664-72.
- 14 Fox AJ, Eliasziw M, Rothwell PM, Schmidt MH, Warlow CP, Barnett HJ. Identification, prognosis, and management of patients with carotid artery near occlusion. *AJNR Am J Neuroradiol.* 2005;26(8):2086-94.
 - 15 Johansson E, Vanoli D, Braten-Johansson I, Law L, Aviv RI, Fox AJ. Near-occlusion is difficult to diagnose with common carotid ultrasound methods. *Neuroradiology.* 2021;63(5):721-30.
 - 16 Bartlett ES, Walters TD, Symons SP, Fox AJ. Diagnosing carotid stenosis near-occlusion by using CT angiography. *AJNR Am J Neuroradiol.* 2006;27(3):632-7.
 - 17 Manrique-Zegarra M, Garcia-Pastor A, Castro-Reyes E, Guzman-De-Villoria JA, Herrera Herrera I, Garrido Morro I, et al. CT angiography for diagnosis of carotid near-occlusion: a digital subtraction angiography validation study. *Neuroradiology.* 2022;64(9):1729-35.
 - 18 Naylor AR, Ricco JB, de Borst GJ, Debus S, de Haro J, Halliday A, et al. Editor's Choice - Management of Atherosclerotic Carotid and Vertebral Artery Disease: 2017 Clinical Practice Guidelines of the European Society for Vascular Surgery (ESVS). *Eur J Vasc Endovasc Surg.* 2018;55(1):3-81.
 - 19 AbuRahma AF, Avgerinos ED, Chang RW, Darling RC, 3rd, Duncan AA, Forbes TL, et al. Society for Vascular Surgery clinical practice guidelines for management of extracranial cerebrovascular disease. *J Vasc Surg.* 2022;75(1S):4S-22S.
 - 20 Naylor R, Rantner B, Ancetti S, de Borst GJ, De Carlo M, Halliday A, Kakkos SK, et al. Editor's Choice - European Society for Vascular Surgery (ESVS) 2023 Clinical Practice Guidelines on the Management of Atherosclerotic Carotid and Vertebral Artery Disease. *Eur J Vasc Endovasc Surg.* 2023 Jan;65(1):7-111
 - 21 Johansson E, Holmgren M, Henze A, Fox AJ. Diagnosing carotid near-occlusion is a difficult task-but it might get easier. *Neuroradiology.* 2022;64(9):1709-14.
 - 22 Akkan K, Ilgit E, Onal B, Cindil E, Solak EP, Oncu F, et al. Endovascular Treatment for Near Occlusion of the Internal Carotid Artery : 30-Day Outcome and Long-Term Follow-Up. *Clin Neuroradiol.* 2018;28(2):245-52.
 - 23 Kim J, Male S, Damania D, Jahromi BS, Tummala RP. Comparison of Carotid Endarterectomy and Stenting for Symptomatic Internal Carotid Artery Near-Occlusion. *AJNR Am J Neuroradiol.* 2019;40(7):1207-12.
 - 24 Terada T, Tsuura M, Matsumoto H, Masuo O, Tsumoto T, Yamaga H, et al. Endovascular treatment for pseudo-occlusion of the internal carotid artery. *Neurosurgery.* 2006;59(2):301-9; discussion -9.
 - 25 de Borst GJ, Antonopoulos CN, Meershoek AJA, Liapis CD. Carotid Artery Near Occlusion: Time to Rethink the Management? *Eur J Vasc Endovasc Surg.* 2020 Aug;60(2):169-170

Acute carotid stent thrombosis (ACST): a review study

Anastasia K. Kouri¹, Konstantinos G. Moulakakis¹, George Geroulakos²

¹ School of Medicine, Department of Vascular Surgery, University Hospital of Patras, Greece

² School of Medicine, National and Kapodistrian University of Athens, Department of Vascular Surgery, Attikon University Hospital, Greece

Abstract:

Objective: Acute carotid stent thrombosis (ACST) is a rare complication of carotid artery stenting (CAS), occurring within 30 days after CAS and can lead to devastating, even lethal consequences. The purpose of this study is to review the current literature on ACST and investigate the potential causative factors and the available therapeutic strategies.

Methods: A search of multiple electronic health databases was conducted. A total of 37 cases reporting acute ACST were retrieved.

Results: There were 33 male and 4 female patients [mean age 68.54 years (SD \pm 7.98 y)]. 21.62% (8 cases) referred to asymptomatic carotid stenosis. The left internal carotid artery (ICA) was the predominant site of carotid stenosis (24/37 cases, 64.86%). In 13(35.1%) of cases ACST occurred intra-procedurally, in 10 (27%) within the first 24 hours, in 13 (35.1%) within the first week after CAS. In 1 (2.7%) case there was late thrombosis 3 weeks after CAS. Inadequate antiplatelet therapy, thrombotic predisposition, or antiplatelet resistance, were described as possible causes in 42.3% of cases. The most common technical intraprocedural anatomic causes leading to ACST were ICA dissection, overlapping stents, plaque protrusion along the stent, and thrombosis of embolic protection devices (EPDs). Treatment varied according to the time of carotid stent thrombosis, the cause, and the patient's neurologic status. Antiplatelet therapy in combination with antithrombotic agents (heparin, warfarin, argatroban), intravenous infusion of platelet glycoprotein IIb/IIIa inhibitors (GPIs), thrombolysis, mechanical thrombectomy, thromboaspiration with thrombolysis, open surgery and re-angioplasty were reported as therapeutic strategies. In the majority of cases clinical improvement with resolution of neurological symptoms or residual neurological deficit was observed. Two deaths (5.4%) were reported.

Conclusion: Although, there is no consensus regarding the management of ACST, thrombolysis, mechanical thrombectomy, thromboaspiration with thrombolysis, open surgery and re-angioplasty have all been used with promising results. The critical points for preventing the devastating outcome are immediate recognition of the thrombosis and rapid revascularization of the damaged tissue.

Keywords: Carotid stent; acute thrombosis; stroke; revascularization

INTRODUCTION

Acute carotid stent thrombosis is a rare complication of carotid artery stenting (CAS), the prevalence of which varies between 0.5% to 0.8%.¹ It is a devastating complication that can lead to a stroke and death and occurs within 30 days after CAS.¹⁻⁴ This serious complication requires early diagnosis and prompt restoration of cerebral perfusion via internal carotid artery (ICA) recanalization to limit ischemic brain damage.⁵ There are several case reports in the literature, but no large series and there are no specific guidelines regarding the ideal strategy for treating ACST. The purpose of this study is to review the current literature on this devastating complication

occurring after CAS to investigate potential etiological factors and to explore available therapeutic strategies and outcomes of treated patients.

METHODS

A multiple search of electronic health databases, including MEDLINE/PUBMED and EMBASE, was performed for all articles published up to June 2022 on carotid stent thrombosis after CAS. Only cases with ACST were included in our study. ACST was defined as those thromboses occurring in the first hours or days after the procedure. Late thromboses (> 30days after CAS) were excluded from the study.

Search strategy

Studies were identified by searching electronic databases and scanning bibliographic references of articles. The National Library of Medicine's Medline database was searched using the PubMed interface and SCOPUS from through June 2022. No language constraints were used. Keywords were selected using medical subject headings (MeSH) for PubMed and MeSH/Emtree for Scopus. The keywords "acute", "carotid stent", and "thrombosis", were used. Databases were searched with an unrestricted search strategy, applying exploded MeSH

Author for correspondence:

Anastasia K. Kouri

School of Medicine, Department of Vascular Surgery,
University Hospital of Patras, Greece, Rion, Achaia, 26504
Tel: +30 6948380805

E-mail: natasa.kouri@gmail.com

doi: 10.59037/nyv9m480

ISSN 2732-7175 / 2023 Hellenic Society of Vascular and
Endovascular Surgery Published by Rotonda Publications
All rights reserved. <https://www.heljves.com>

and keywords combined with the Boolean operator AND to retrieve relevant reports. A second-level search included a manual screen of the reference lists of the articles identified through the electronic search.

Age and sex, degree and location of stenosis, incidence, perioperative antiplatelet medication, cause of ACST, type of treatment, and outcome were retrieved and analyzed.

RESULTS

The search identified 277 records in total after applying the inclusion criteria. All studies were reviewed and a total of 25 studies, describing the outcome of 37 patients with ACST, met the inclusion criteria.^{1-3,6-9,11,13,15-30} The included studies were case reports and small series. In the present study, 33 out of 37 patients were male with a mean age of 68.54 years (SD \pm 7.98, min 44, max 82 y), and only 21.62% (8 cases) were treated with CAS for asymptomatic carotid stenosis. In the majority of cases (89.19%) mono or dual antiplatelet therapy was used pre-procedurally. The left internal carotid artery (LICA) was the predominant site of carotid stenosis (24/37 cases, 64,86%). In 13 (35.1%) cases ACST occurred intra-procedurally, while in 10 (27%) patients, stent thrombosis occurred within the first 24 hours. The remaining 13 (35.1%) cases reported

ACST within the first week after CAS. In 1(2.7%) case there was a thrombosis 3 weeks after CAS. Overall, two deaths (5.4%) were reported.

Etiology

The cause of thrombosis was not defined in 11 out of the 37 cases (Table 1).

Inadequate antiplatelet therapy, thrombotic predisposition or antiplatelet resistance were described as possible causes in 11(42.3%) of cases (table 1). Three cases of hypercoagulation (3/26, 11.1%) were described due to malignancy^{15,22,27} and one more was attributed to atrial fibrillation by Setacci et al.²¹

Technical intraprocedural anatomical causes which led to ACST were identified as follows: ICA dissection in 2 cases¹¹, plaque protrusion across the stent in one patient²⁷, overlapping stents in 3 cases (due to malposition in two of them and a long common carotid stenosis in one case)²⁷, percutaneous transluminal angioplasty (PTA) failure in 3 reports^{11,20,25} and embolic protection devices (EPD) complications in 5 patients^{1,16,24} (4 cases of EPD thrombosis and 1 case of ICA dissection). A combination of the abovementioned causes was reported in 4 cases (Table 1).

Table 1: Cases with acute carotid stent thrombosis.

	First Author	Year	Age/sex	Site of Stenosis/Grade	S/A	Onset	Preprocedural antiplatelet/antithrombotic drugs	Cause of ACST (according to Authors)
1	Tong ⁸	2000	44/M	LICA/70%	A	Intraprocedurally	ND	ND
2	Chaturvedi ¹²	2001	63/F	LICA/sever	S	12 hours	ASA	ND
3	Chaturvedi ¹²	2001	57/M	LICA/ND	S	3 days	NONE	ND
4	Hamann ⁹	2002	76/M	RICA/70%	S	4 days	ASA and heparin	Antiplatelet therapy ceased
5	Owens ¹⁸	2003	65/M	LICA/70%	S	Intraprocedurally	ND	ND
6	Bush ⁷	2003	68/M	RICA /90%	S	15 minutes	DAPT	ND
7	Steiner Boker ⁶	2004	64/F	RICA/85%	S	Intraprocedurally	DAPT	Hypercoagulation
8	Setacci ²¹	2005	82/M	LICA/80%	S	2 days	DAPT	ND
9	Setacci ²¹	2005	78/M	LICA/85%	S	4 days	DAPT	DAPT therapy ceased, thrombocytopenia
10	Setacci ²¹	2005	72/M	LICA/80%	S	2 hours	ASA and heparin	AF, multiple cardiac embolism
11	Masuo ¹⁹	2006	71/M	LICA/severe	S	3 days	DAPT and heparin	lacking periproced. antithrombotic medication
12	Buhk ²²	2006	78/M	LICA/80%	S	3 weeks	DAPT → heparine	Antiplatelet therapy ceased, bladder cancer
13	Seo ²⁵	2008	63/M	LICA/85%	A	Intraprocedurally	DAPT	postdilatation filling stent defect
14	Iancu ¹¹	2010	65/M	LICA/80%	S	Intraprocedurally	DAPT	postdilatation carotid dissection
15	Iancu ¹¹	2010	70/M	RICA/80%	S	Intraprocedurally	DAPT	Balloon burst
16	Dhall ¹⁷	2010	62/M	LICA/90%	S	Intraprocedurally	DAPT	ND
17	Choi ²³	2012	69/M	RICA/83%	S	9 days	DAPT	ND
18	Choi ²³	2012	68/M	LICA/72%	S	4 days	DAPT	DAPT resistance
19	Kanemaru ¹⁵	2013	77/M	RICA/ 90%	A	6 days	DAPT and cilostazol	Hypercoagulation/ bladder cancer
20	Markatis ¹³	2012	67/M	LICA/95%	S	2 days	CLO	DAPT Discontinuation
21	Kim ²⁴	2013	75/M	LICA 90%	S	Intraprocedurally	DAPT	EPD thrombosis
22	Kim ²⁴	2013	73/M	ND	A	Intraprocedurally	DAPT	EPD thrombosis
23	Kim ²⁴	2013	51/M	ND	S	Intraprocedurally	DAPT	EPD thrombosis

	First Author	Year	Age/sex	Site of Stenosis/Grade	S/A	Onset	Preprocedural antiplatelet/antithrombotic drugs	Cause of ACST (according to Authors)
24	Munich ¹⁶	2014	70/M	LICA/90%	S	Intraprocedurally	DAPT	EPD thrombosis
25	Köklü ²⁶	2015	73/M	LICA/95%	S	24 hours	ASA	DAPT resistance
26	Moulakakis ²⁷	2017	67/M	RICA/90%	S	1 hour	DAPT	Dissection from EPD, 360° RICA kinking
27	Moulakakis ²⁷	2017	74/M	LICA/80%	S	2 hours	Nadroparin calcium	overlapping stents, malignancy
28	Moulakakis ²⁷	2017	73/F	LCCA/80%	S	3 days	DAPT	overlapping stents, malignancy
29	Moulakakis ²⁷	2017	66/M	LICA/80%	S	4 days	DAPT	overlapping stents
30	Cvjetko ²⁹	2017	68/F	RICA/70%	ND	90 minutes	DAPT	ND
31	Cvjetko ²⁹	2017	80/M	LICA/70%	A	4 days	DAPT	ND
32	Moulakakis ¹	2018	66/M	RICA/90%	S	Intraprocedurally	ASA	Plaque protrusion across the stent
33	Moulakakis ¹	2018	72/M	RICA/severe	A	1 hour	ND	ND
34	Hu ²⁰	2018	79/M	LICA occlusion	A	Intraprocedurally	DAPT	Stent not fully adhered to vessel
35	Kahyaoglu ³	2018	66/M	LICA/70%	S	3 hours	DAPT	DAPT Discontinuation
36	Toljan ³⁰	2019	55/M	LICA occlusion	A	2 hours	DAPT	CYP2C19 & MDR1
37	Wei wei ²⁸	2021	69/M	LICA/90%	S	5 days	DAPT	CYP2C19 heterozygote

F- female, M- male, ND- not determined, ASA- aspirin, CLO- clopidogrel, DAPT: Dual antiplatelet therapy(ASA and clopidogrel or ticlopidine), A-asymptomatic, S- symptomatic, LICA- left internal carotid artery, RICA- right internal carotid artery, CEA- carotid endarterectomy, EPD- embolic protection device

Therapeutic Management

Antiplatelet therapy in combination with antithrombotic agents

Eight patients were treated with antiplatelet therapy (single or dual) in combination with antithrombotic agents (low molecular weight heparin, warfarin, argatroban) or intravenous (IV) infusion of GPIs.^{8,15,25,26,27} Data on the use of GPIs are relatively limited, and fatal intracranial hemorrhage has been reported as a complication⁵. Abciximab was used alone or in combination with other thrombolytic agents and showed efficacy in dissolving an in-stent thrombus (IV bolus dosage of 0.25mg/kg and a 0.125mg/kg intra-arterially, followed by IV infusion of 0.125mg/kg/min for further 12 hours).^{6,7,8}

In the majority of cases, resolution of neurological symptoms or residual paresis was observed. In one case treated with aspirin alone, death occurred (**Table 2**).²

Thrombolysis ± Re-Angioplasty

In 12 patients thrombolysis was performed which was unsuccessful in 4 of them and further treatment was needed. Thrombolysis in patients with acute ischemic stroke attributed to ICA occlusion can be infused either intra-arterially or IV. Several thrombolytic agents such as streptokinase, urokinase, tenecteplase, or rTPA have been used for the treatment of acute ACST intra-arterially with complete, partial, or even unsuccessful clot resolution.^{2,7,10,11,12,13} A clinical improvement and a patent stent in the majority of cases were described (**Table 2**). Studies have recorded the beneficial effect of IV thrombolysis^{9,10}, however, an increase in death and intracranial bleeding were also documented.⁶ In one case treated with urokinase, a death occurred (**Table 2**).²

3 cases were treated with re-angioplasty or stenting. Owens et al reported thrombolysis and repeat angioplasty, leading to ICA thrombosis and rupture.¹⁸ Masuo et al described an intraprocedural ACST treated with redo in stent PTA using an EPD, followed by intravenous heparin infusion for 7 days with a residual mild hemiparesis.¹⁹ Finally, Hu et al reported intraprocedural in stent thrombosis treated with microcatheter infusion of rt-PA and re-angioplasty.²⁰

Mechanical thrombectomy or thromboaspiration with or without thrombolysis

8 patients underwent mechanical thrombectomy with or without thrombolysis. The Penumbra system showed promising results with complete recanalization and neurological improvement in 3 patients (**Table 2**).²⁴ Thromboaspiration combined with thrombolysis or anticoagulants (abciximab) has shown clinical improvement and stent recanalization.^{16,17,28,30} It offers an alternative, however EPD occlusion has been reported.^{15,16} Dhall et al have reported complete patency restoration with the use of a thromboaspiration catheter before EPD withdrawal.¹⁷ Mechanical thrombectomy and stenting were associated with higher recanalization rates and improved functional status when compared to intra-arterial thrombolysis.¹²

Open Surgical Exploration

12 patients underwent surgical exploration (**Table 2**), due to described major neurological deterioration.^{1,13,18,21,23,29} Strategies such as carotid thromboendarterectomy and stent explantation, open surgical thrombectomy without stent removal, primary or patch closure, use of shunt or not, and even bypass from superficial temporal artery to middle cerebral artery (STA-MCA) were reported.

Table 2: Cases with acute carotid stent thrombosis. F- female, M- male, ND- not determined, ASA- aspirin, CLO- clopidogrel, ,

	First Author	Stroke severity and symptoms	Treatment	Outcome
1	Tong ⁸	None	Abciximab IV bolus	Resolution of neurological symptoms /stent patent
2	Chaturvedi ²	None	750000IU urokinase	Death
3	Chaturvedi ²	Right hemiplegia	ASA	Death
4	Hamann ⁹	Hemiparesis, left hemianopsia	70mg rt-PA & heparin	Resolution of neurological symptoms/ stent patent
5	Owens ¹⁸	Right upper extremity weakness	Thrombolysis, repeat angioplasty/ICA thrombolysis & rupture- stent removal	Motor deficits
6	Bush ⁷	Unconscious, hypotension, seizures	Mechanical thrombectomy & iv abciximab	Resolution of neurological symptoms /stent patent
7	Steiner-Boker ⁶	Mild left facial paresis & dysarthria	Intracarotid 5mg rt-PA - intraarterial & iv for 12 hours abciximab	Neurological improvement/ stent patent
8	Setacci ²¹	Crescendo TIAs	Endarterectomy and Stent removal	Neurological improvement
9	Setacci ²¹	Decreased level of consciousness	Endarterectomy and Stent removal	Gradual improvement from the stroke
10	Setacci ²¹	Left hemiplegia	Surgical thrombectomy without stent removal	Good recovery/ stent patent
11	Masuo ¹⁹	Right hemiparesis, motor aphasia	In-stent PTA & EPD& iv heparin for 7 days	Mild right hemiparesis
12	Buhk ²²	Aphasia, right hemiparesis	Antiplatelet therapy & heparin	Minor hemiparesis & slight aphasia/ thrombus resolution, stent patent
13	Seo ²⁵	None	IV tirofiban	No neurological deficit/ stent patent
14	Iancu ¹¹	Hemodynamic instability, contralateral hemiplegia, unconsciousness	Bolus streptokinase	No neurological deficit/ stent patent
15	Iancu ¹¹	Unconsciousness	Intrathrombus tenecteplase & balloon angioplasty	No neurological deficit/ normal intrastent velocities
16	Dhall ¹⁷	Seizures, hemodynamic instability	Urokinase, abciximab, thromboaspiration	Clinical improvement/ stent recanalization
17	Choi ²³	Hemiparesis, dysarthria, left facial palsy	STA-MCA anastomosis	Left hemiparesis & dysarthria
18	Choi ²³	Hemiparesis, dysarthria, right facial palsy	Iv rt-PA, intra-arterial thrombolysis, STA-MCA anastomosis	Right hemiparesis
19	Kanemaru ¹⁵	None	ASA & CLO& cilostazol & warfarin & argatroban	Thrombus resolution
20	Markatis ¹³	Right paresis, numbness	Heparin, endarterectomy, stent removal, thrombectomy, primary closure	Minor numbness of three digits on the right hand
21	Kim ²⁴	None	Mechanical thrombectomy (Penumbra system)	Complete recanalization
22	Kim ²⁴	Global aphasia	Mechanical thrombectomy (Penumbra system)	Complete recanalization/ neurological improvement
23	Kim ²⁴	Hemiparesis, impaired mentality	Mechanical thrombectomy (Penumbra system)	Complete recanalization/ neurological improvement
24	Munich ¹⁶	ND	Unsuccessful intraarterial verapamil & abciximab, thrombus aspiration	Good recovery/residual 25-30% stenosis
25	Köklü ²⁶	Right hemiplegia, dysarthria	Unfractionated heparin & ticlodipine	Residual paresis
26	Moulakakis ²⁷	Left hemiparesis	Thrombus aspiration, surgical exploration, eversion CEA with stent removal	Clinical improvement, residual arm paresis
27	Moulakakis ²⁷	Aphasia, right hemiparesis	Intrathrombus urokinase & stenting	Clinical improvement, residual arm paresis
28	Moulakakis ²⁷	Right arm paresis	Tinzaparin	Residual arm paresis/30 months post-op no paresis
29	Moulakakis ²⁷	Aphasia, right hemiparesis	ASA, CLO nadroparin	Mild speech impairment
30	Cvjetko ²⁹	Contralateral hemiplegia, aphasia	Endarterectomy, stent removal, primary closure	Rankin 1

	First Author	Stroke severity and symptoms	Treatment	Outcome
31	Cvjetko ²⁹	TIA's	Endarterectomy, stent removal, Fogarty thrombectomy	Rankin 3
32	Moulakakis ¹	Left hemiparesis	Endarterectomy & stent removal	Good recovery
33	Moulakakis ¹	Hemodynamic instability	Unsuccessful intraarterial thrombolysis & actilyse, endarterectomy & stent removal	No neurological deficit
34	Hu ²⁰	None	rt-PA through microcatheter, redilatation of the stent	No neurological deficits/ stent patent
35	Kahyaoglu ³	Motor aphasia, right hemiplegia	CLO, unfractionated heparin iv, intaarterial rt-PA	Left arm weakness/ stent recanalization
36	Toljan ³⁰	Global aphasia, right hemiparesis	Thrombus aspiration, alteplase, iv eptifibatide	Good recovery/ stent patent
37	Wei wei ²⁸	Right limb weakness, right facial paralysis, hemianalgesia	Thrombus aspiration & tirofiban	Rankin 1

DAPT: Dual antiplatelet therapy(ASA and clopidogrel), A- asymptomatic, S- symptomatic, LICA- left internal carotid artery, RICA- right internal carotid artery, CEA- carotid endarterectomy, EPD- embolic protection device

DISCUSSION

Acute carotid stent thrombosis remains a rare complication of CAS, occurring during or after less than 1% of procedures.¹ According to the available literature, 37 cases reporting acute carotid stent thrombosis in the early period (<30 days) have been recognized. Many factors have been implicated as responsible for ACST. Our study showed that the predominant factors for carotid stent thrombosis are inadequate antiplatelet therapy, thrombotic predisposition, and the antiplatelet resistance.³ Furthermore, technical intraprocedural anatomical causes predisposing to carotid stent thrombosis are local vessel dissection or intimal injury leading to platelet adhesion and thus thrombus formation^{11,25}, plaque protrusion promoting thrombosis, kinking and even coiling of the distal part of ICA²⁷, vasospasm, stent underexpansion which impairs stent's thrombogenicity itself²⁸, overlapping carotid stents²⁷ and EPD occlusion.^{4,16,24} It is supported that EPD occlusion and carotid stent thrombosis are sequential events as they have been attributed to similar mechanisms.^{4,16,24}

Our study showed heterogeneity in the type of treatment used, the severity of the patient's neurological condition, and the extent of brain damage. In the majority of cases, clinical improvement was observed with a resolution of neurological symptoms or residual neurological deficit. Two deaths (5.4%) were reported. However, this rate might be underestimated by the fact that ACST cases with a fatal outcome may have been avoided for publication. Thrombolysis, mechanical thrombectomy, thromboaspiration with thrombolysis, open surgical therapy, and re-angioplasty have all been used, depending on the time of thrombosis, cause, and neurological status of the patient, with promising results. The main goal of ACST treatment is to promptly remove the source of thrombus to limit ischemia time, reperfusion injury, and potential post-procedure related intracranial hemorrhage.

Emergent removal of the thrombosed stent is indicated in ACST patients with immediate neurological deterioration, especially when the in-stent thrombosis is not associated with intracranial carotid branch thrombosis. The emergency operation has the risk of clot dislocation due to surgical maneuvers

and therefore demands extended site exposure and careful preparation to protect distal cerebral embolization.¹

Several studies have documented the beneficial effect of intra-arterial thrombolysis.^{2,6,7,9-13} It can be used rapidly especially when ACST occurs intraprocedurally. Although local intra-arterial thrombolysis might have a high recanalization rate, however, intraluminal manipulation of wires and catheters combined with thrombus lysis can cause clot fragmentation and therefore distal cerebral occlusion. The residual thrombus within the stent predisposes to restenosis or even re-thrombosis of the stent. Intra-arterial thrombolysis with redo PTA or stenting may be another alternative for treating ACST.¹⁸⁻²⁰ It should be emphasized that redo PTA or stenting itself carries a risk of damaging the stent's stability. In addition, one study showed that overlapping carotid stents predispose to thrombosis.¹

A combination of methods such as mechanical thrombectomy with thrombus aspiration may be used according to ASA/ AHA guidelines in patients with large segment occlusion who have not responded to intravenous thrombolysis and should be performed only by certified experts.³¹ According to literature data, mechanical thrombectomy and stenting may be associated with higher recanalization rates and improved functional status when compared to intra-arterial thrombolysis¹².

In the most comprehensive review up to date in which 26 cases of early carotid stent thrombosis were presented an algorithm for the management has been proposed.¹ This algorithm distinguishes whether the complication occurred intra- or post-procedurally. In the latter case, an imaging study initially such as carotid duplex examination, followed by digital subtraction angiography or computed tomographic angiography in suspicion of distal extension of carotid thrombosis is recommended to evaluate the level of thrombosis. Once confirmed, then percutaneous mechanical thrombectomy, thromboaspiration and thrombolysis or thrombolysis with or without IIb/IIIa receptor inhibitors are suggested. Then, if partial or residual intrastent thrombosis with no distal cerebral extension is documented surgical exploration can be used. If carotid stent thrombosis occurs intraprocedurally immedi-

ate treatment with percutaneous mechanical thrombectomy, thromboaspiration and thrombolysis or thrombolysis with or without IIb/IIIa receptor inhibitors should be initiated. If the thrombus is refractory, surgical exploration should be considered. Tirofiban has been suggested mainly due to its short platelet-bound half-life and long plasma half-life predisposing to lower hemorrhagic risk¹.

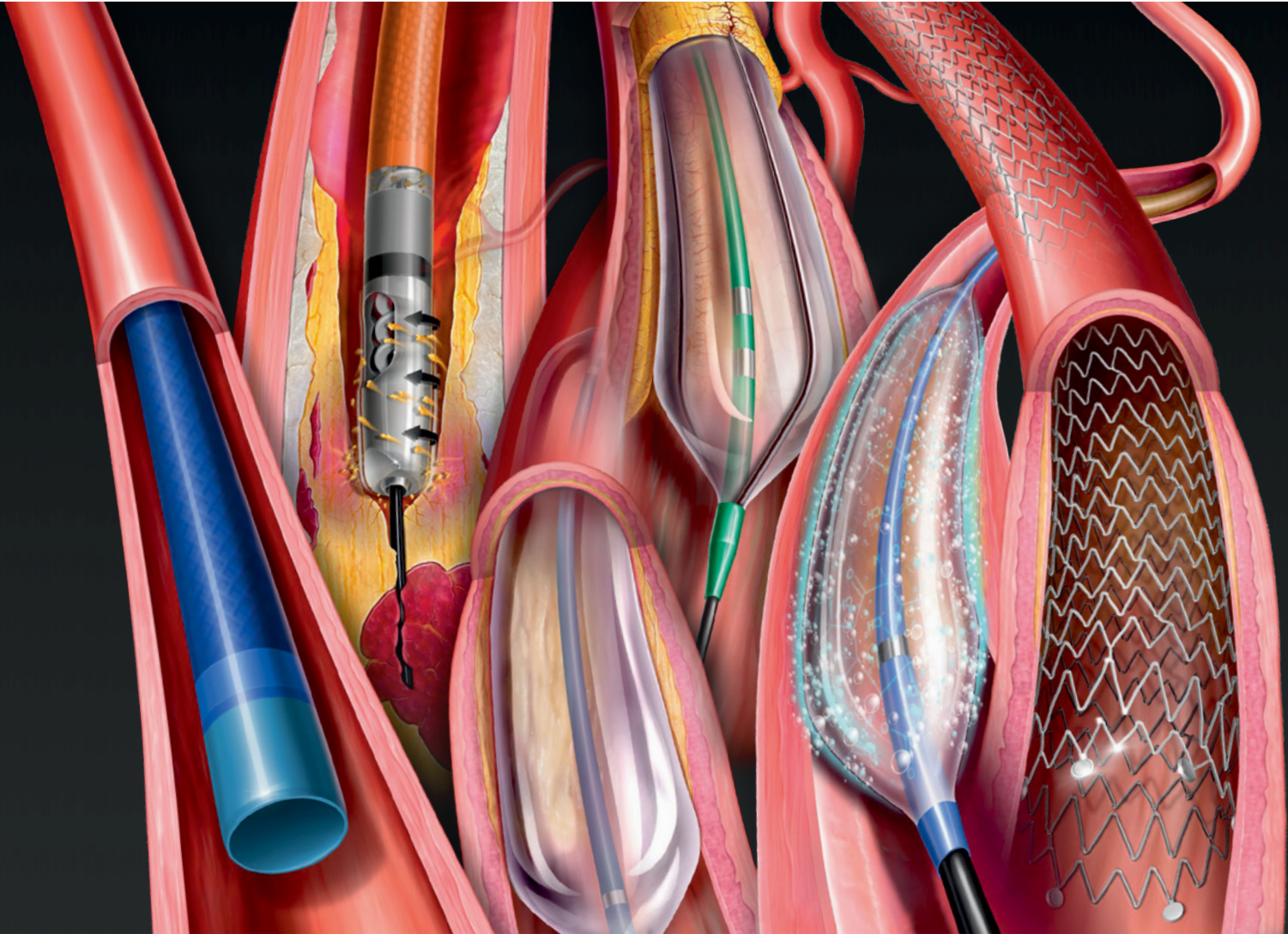
In conclusion, acute carotid stent thrombosis is a rare complication of CAS with potentially devastating even lethal outcomes. Although, there is no consensus on its management, thrombolysis, mechanical thrombectomy, thromboaspiration with thrombolysis, open surgical treatment, and re-angioplasty have all been used, depending on the stent thrombosis time and cause with promising results. The critical points in preventing a catastrophic outcome are immediate recognition of thrombosis and rapid revascularization of the damaged tissue.

REFERENCES

- Moulakakis KG, Mylonas SN, Lazaris A, Tsvigoulis G, Kakis J, Sfyroeras GS et al. Acute Carotid Stent Thrombosis: A Comprehensive Review. *Vasc Endovascular Surg*. 2016;50:511-521.
- Chaturvedi S, Sohrab S, Tselis A. Carotid stent thrombosis: report of 2 fatal cases. *Stroke*. 2001;32:2700-2.
- Kahyaoglu M, Velioglu M, Gecmen C, Kalayci A, Cakmak EO, Izgi IA. Acute carotid stent thrombosis. *J Cardiovasc Thorac Res*. 2018;10:243-245.
- Kwon OK, Kim SH, Jacobsen EA, Marks MP. Clinical implications of internal carotid artery flow impairment caused by filter occlusion during carotid artery stenting. *AJNR Am J Neuroradiol*. 2012;33:494-9.
- Adams HP Jr, Effron MB, Torner J, Dávalos A, Frayne J, Teal P et al.; AbESTT-II Investigators. Emergency administration of abciximab for treatment of patients with acute ischemic stroke: results of an international phase III trial: Abciximab in Emergency Treatment of Stroke Trial (AbESTT-II). *Stroke*. 2008;39:87-99.
- Steiner-Böker S, Cejna M, Nasel C, Minar E, Kopp CW. Successful revascularization of acute carotid stent thrombosis by facilitated thrombolysis. *AJNR Am J Neuroradiol*. 2004;25:1411-3.
- SRTEINER RL, Bhama JK, Lin PH, Lumsden AB. Transient ischemic attack due to early carotid stent thrombosis: successful rescue with rheolytic thrombectomy and systemic abciximab. *J Endovasc Ther*. 2003;10:870-4.
- Tong FC, Cloft HJ, Joseph GJ, Samuels OB, Dion JE. Abciximab rescue in acute carotid stent thrombosis. *AJNR Am J Neuroradiol*. 2000;21:1750-2.
- Hamann GF, Liebetrau M, Pfefferkorn T, Heiss MM. Successful systemic thrombolysis for carotid stent thrombosis. *Eur Neurol*. 2002;48:37-9.
- Paciaroni M, Balucani C, Agnelli G, Caso V, Silvestrelli G, Grotta JC, et al. Systemic thrombolysis in patients with acute ischemic stroke and Internal Carotid ARtery Occlusion: the ICARO study. *Stroke*. 2012;43:125-30.
- H A, Grosz C, Lazar A. Acute carotid stent thrombosis: review of the literature and long-term follow-up. *Cardiovasc Revasc Med*. 2010;11:110-3.
- Kappelhof M, Marquering HA, Berkhemer OA, Majoie CB. Intra-arterial treatment of patients with acute ischemic stroke and internal carotid artery occlusion: a literature review. *J Neurointerv Surg*. 2015;7:8-15.
- Markatis F, Petrosyan A, Abdulamit T, Bergeron P. Acute carotid stent thrombosis: a case of surgical revascularization and review of treatment options. *Vascular*. 2012;20:217-20.
- Jauch EC, Saver JL, Adams HP Jr, Bruno A, Connors JJ, Demaerschalk BM et al.; American Heart Association Stroke Council; Council on Cardiovascular Nursing; Council on Peripheral Vascular Disease; Council on Clinical Cardiology. Guidelines for the early management of patients with acute ischemic stroke: a guideline for healthcare professionals from the American Heart Association/American Stroke Association. *Stroke*. 2013;44:870-947.
- Kanemaru K, Nishiyama Y, Yoshioka H, Satoh K, Hashimoto K, Hanihara M et al. In-stent thrombosis after carotid artery stenting despite sufficient antiplatelet therapy in a bladder cancer patient. *J Stroke Cerebrovasc Dis*. 2013;22:1196-200.
- Munich S, Moftakhar R, Lopes D. Recanalization of acute carotid stent occlusion using Penumbra 4Max aspiration catheter: technical report and mreview of rescue strategies for acute carotid stent occlusion. *BMJ Case Rep*. 2013 14;2013: bcr2013010706.
- Dhall A, Malani SK, Chadha DS. Thrombosuction for procedural acute thrombosis during high-risk carotid angioplasty--a case report. *J Invasive Cardiol*. 2010 Aug;22(8):E144-6. PMID: 20679679.
- Owens EL, Kumins NH, Bergan JJ, Sparks SR. Surgical management of acute complications and critical restenosis following carotid artery stenting. *Ann Vasc Surg*. 2002 Mar;16(2):168-75. doi: 10.1007/s10016-001-0152-2. PMID: 11972247.
- Masuo O, Terada T, Matsuda Y, Ogura M, Tsumoto T, Yamaga H, Itakura T. Successful recanalization by in-stent percutaneous transluminal angioplasty with distal protection for acute carotid stent thrombosis. *Neurol Med Chir (Tokyo)*. 2006;46:495-9.
- Hu W, Wang L, Wang G. Acute In-Stent Thrombosis after Carotid Angioplasty and Stenting: A Case Report and Literature Review. *Interv Neurol*. 2018;7:265-270.
- Setacci C, de Donato G, Setacci F, Chisci E, Cappelli A, Pieraccini M et al. A. Surgical management of acute carotid thrombosis after carotid stenting: a report of three cases. *J Vasc Surg*. 2005;42:993-6.
- Buhk JH, Wellmer A, Knauth M. Late in-stent thrombosis following carotid angioplasty and stenting. *Neurology*.

- 2006;66:1594-6.
- 24 Choi HJ, Kim ST, Jeong YG, Jeong HW. Superficial temporal artery-middle cerebral artery anastomosis for internal carotid artery occlusion by subacute in-stent thrombosis after carotid artery stenting. *J Korean Neurosurg Soc.* 2012;52:551-4.
- 25 Kim YW, Kang DH, Hwang JH, Park J, Hwang YH, Kim YS. Rescue strategy for acute carotid stent thrombosis during carotid stenting with distal filter protection using forced arterial suction thrombectomy with a reperfusion catheter of the Penumbra System: a technical note. *Acta Neurochir (Wien).* 2013;155:1583-8.
- 26 Seo KD, Lee KO, Kim DJ, Lee KY. Rescue use of tirofiban for acute carotid in-stent thrombosis. *Yonsei Med J.* 2008;49:163-6.
- 27 Köklü E, Arslan Ş, Yüksel İÖ, Bayar N, Koç P. Acute Carotid Artery Stent Thrombosis Due to Dual Antiplatelet Resistance. *Cardiovasc Intervent Radiol.* 2015;38:1011-4.
- 28 Moulakakis KG, Kakisis J, Tsivgoulis G, Zymvragoudakis V, Spiliopoulos S, Lazaris A et al. Acute Early Carotid Stent Thrombosis: A Case Series. *Ann Vasc Surg.* 2017;45: 69-78.
- 29 Wei W, Wang Y, Wang P, Li Z. Revascularization of acute stent thrombosis after carotid artery stenting in a CYP2C19*2 heterozygote patient. *J Int Med Res.* 2021;49:3000605211001191.
- 30 Cvjetko I, Đaković Bacalja I, Cvjetko T. Acute Carotid Artery Stent Thrombosis. *Cardiovasc Intervent Radiol.* 2018;41:355-356
- 31 Toljan K, Jovanović I, Starčević K, Ljevak J, Blažević N, Radoš M, Poljaković Z. Acute Carotid Stent Thrombosis in an Ultrarapid Clopidogrel Metabolizer: Case Report and Literature Review. *Vasc Endovascular Surg.* 2019;53:602-605.
- 32 Powers WJ, Rabinstein AA, Ackerson T, Adeoye OM, Bambakidis NC, Becker K, et al. American Heart Association Stroke Council. 2018 Guidelines for the Early Management of Patients With Acute Ischemic Stroke: A Guideline for Healthcare Professionals From the American Heart Association/American Stroke Association. *Stroke.* 2018;49:e46-e110.

Innovative solutions shaping the future of **PAD** care



Access

Halo One™

Thin-Walled Guiding Sheath

Crosser™

CTO Recanalization Catheter

Restore

Rotarex™ S

Rotational
Atherothrombectomy Catheter

Ultraverse™

PTA Dilatation Catheter

UltraScore™

Focused Force PTA Balloon

Maintain

Lutonix™ 035

Drug Coated Balloon PTA Catheter

Lutonix™ 018

Drug Coated Balloon PTA Catheter

Lutonix™ 014

Drug Coated Balloon PTA Catheter

LifeStent™

Vascular Stent System

Please consult product labels and instructions for use for indications, contraindications, hazards, warnings, and precautions.
© 2021 BDB|TheBD|Logo, Aspirex, Atlas, Atlas|Bena|Presto and Venovo trademarks of Becton, Dickinson and Company or an affiliate. Illustrations by Mike Austin
Copyright © 2021. All Rights Reserved. Bard has joined BD. Straub has joined BD. BD- 90857



Cilos[®]

cilostazol



Qualitative and Quantitative Composition: cilostazol 50 mg και 100 mg

For more information, contact WinMedica's scientific department




www.winmedica.gr

1-3 Oidipodos str., & Attiki Odos Turnoff 33-35, Chalandri - 15238 - Athens. Tel.: 210 7488 821, Order Tel.: 210 7488 839,
E-mail: info@winmedica.gr. THESSALONIKI: 74 Ethnikis Antistaseos & Aiantos, 55133, Tel.: 2310 488658. www.winmedica.gr

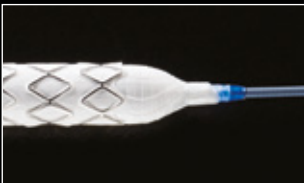GORE® VIABAHN® VBX Balloon Expandable Endoprosthesis

Flexible Strength. Proven Success.



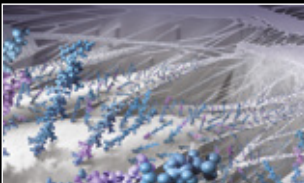
The *only* BX stent graft with stainless steel independent rings

- Enhances flexibility and conformability
- Minimizes foreshortening
- Provides high radial strength



The *only* BX stent graft with a semi-compliant covered balloon

- Enables diameter customization
- Improves device retention on the catheter while tracking in tortuous anatomy and tight angles



The *only* BX stent graft with heparin coating

- Proven heparin bonding technology for lasting thromboresistance*



Broadest offering of diameters and lengths

- The longest BX stent graft
- The biggest max post-dilated stent diameter BX stent graft



Proven leader in stent graft technology

- 20 years of peripheral stent graft clinical experience
- Employs the stent graft technology of GORE® VIABAHN® Endoprosthesis

*Carmeda AB. CBAS® Heparin Surface Reference List. Uplands Väsby, Sweden: Carmeda AB; 2017. [Reference List]. <http://www.carmeda.se/selected-reading>. Published April 25, 2017. Accessed May 1, 2017.



W. L. GORE & ASSOCIATES, INC.

Flagstaff, AZ 86004

+65.67332882 (Asia Pacific) 800.437.8181 (United States)
00800.6334.4673 (Europe) 928.779.2771 (United States)

goremedical.com/vbx

Products listed may not be available in all markets.

BARD® and LIFESTREAM are trademarks and / or registered trademarks of C. R. Bard, Inc.
CBAS is a trademark of Carmeda AB, a wholly owned subsidiary of W. L. Gore & Associates, Inc.
GORE®, VBX, VIABAHN®, and designs are trademarks of W. L. & Gore Associates.
© 2017 W. L. & Gore Associates GmbH AW3508-EN1 OCTOBER 2017

Emergency management of life-threatening iatrogenic femoral artery injuries - report of four cases

George Galyfos, Alexandros Chamzin, Georgios Charalampopoulos, Nikolaos Alexakis, Frangiska Sigala, Konstantinos Filis

Vascular Surgery Unit, First Department of Propedeutic Surgery, National and Kapodistrian University of Athens, Hippocraton Hospital, Athens, Greece

Abstract:

Iatrogenic vascular injuries (IVIs) have increased in the last decades due to the increase in endovascular interventions. The common femoral artery (CFA) is a very common location of IVI. Although many cases are treated conservatively or with minimally invasive techniques, management of life-threatening IVIs may be quite challenging. This report aims to present four uncommon cases with life-threatening iatrogenic CFA injuries that were treated with open surgery and discuss on the proper management.

INTRODUCTION

Iatrogenic vascular injuries (IVIs) have increased in number during the last decades, with an estimated incidence of more than one third of all vascular trauma cases.¹ Due to the increase of endovascular procedures for the treatment of coronary artery disease (CAD) and peripheral artery disease (PAD), percutaneous arterial puncture and sheath introduction has become a very common practice.² There are several options considering the access vessel for performing such endovascular procedures although the common femoral artery (CFA) remains very popular, especially for more complex procedures.³ The occurrence of iatrogenic complications after CFA puncture including haemorrhage, pseudoaneurysm (PSA) formation or acute thrombosis depends on several factors such as length of operation, type of the sheath, antithrombotic treatment, obesity, performance of puncture under ultrasonographic guidance or not, adequate compression, the presence of PAD and others.^{2,4}

When the injury is small or stable, more conservative treatments such as compression or ultrasound-guided thrombin injection (UGTI) have been applied with success.⁵ However, when the injury is life-threatening and the patient becomes unstable, an emergency repair is indicated.² In many cases, establishing control of the bleeding and repairing the

injury may be challenging, especially when the hematoma is of massive size. This report aims to present four unusual cases with a life-threatening IVI post catheterization of the CFA, and discuss on proper management.

CASE 1

A 55-year-old female patient with a history of PAD and resistant arterial hypertension (under triple antihypertensive treatment; bilateral renal artery stenosis; and an older occluded right renal artery stent) was scheduled by our nephrology department to undergo endovascular repair of the left renal artery stenosis as well as repair of the significant iliac artery disease. No vascular surgeon was previously informed to evaluate the patient. The patient was referred directly to a radiology department in another hospital where she underwent an angioplasty and stenting of the left renal artery and kissing stenting of the common iliac arteries (in total 4 new stents) (see **Figure 1A**). The procedure was performed percutaneously via femoral access (6Fr sheaths) and the patient was transferred back to our nephrology department with pressure bandages placed bilaterally. Within the following hours, the patient presented a huge right-sided hematoma expanding from the upper femoral area towards the right abdominal wall up to the right hypochondrium (**Figure 1B**). There was a significant drop of haemoglobin and the patient quickly became unstable. She lost consciousness and was intubated. Vasoconstriction treatment and blood transfusions were initiated promptly.

The patient underwent an emergency surgery. Due to the cephalad expansion of the bleeding, an oblique retroperitoneal approach was not feasible, and therefore a middle abdominal incision was selected. During the dissection of the abdominal wall, a massive bleeding originated from the right extraperitoneal area that was initially managed with gauge packing. After entering the abdominal cavity, the right external iliac artery was dissected below the level of the stent and clamped. Immediately, the patient was stabilized by the anaesthesiologists. Thereafter, a large femoral incision was

Author for correspondence:

George Galyfos

Vascular Surgery Unit, First Department of Propedeutic Surgery, National and Kapodistrian University of Athens, Hippocraton Hospital, 114 Vasilissis Sofias Avenue, 11527, Athens, Greece

Tel: +30 2132088132

Fax: +30 2107707574

E-mail: georgegalyfos@hotmail.com

doi: 10.59037/ye0vdr55

ISSN 2732-7175 / 2023 Hellenic Society of Vascular and Endovascular Surgery Published by Rotonda Publications
All rights reserved. <https://www.heljves.com>

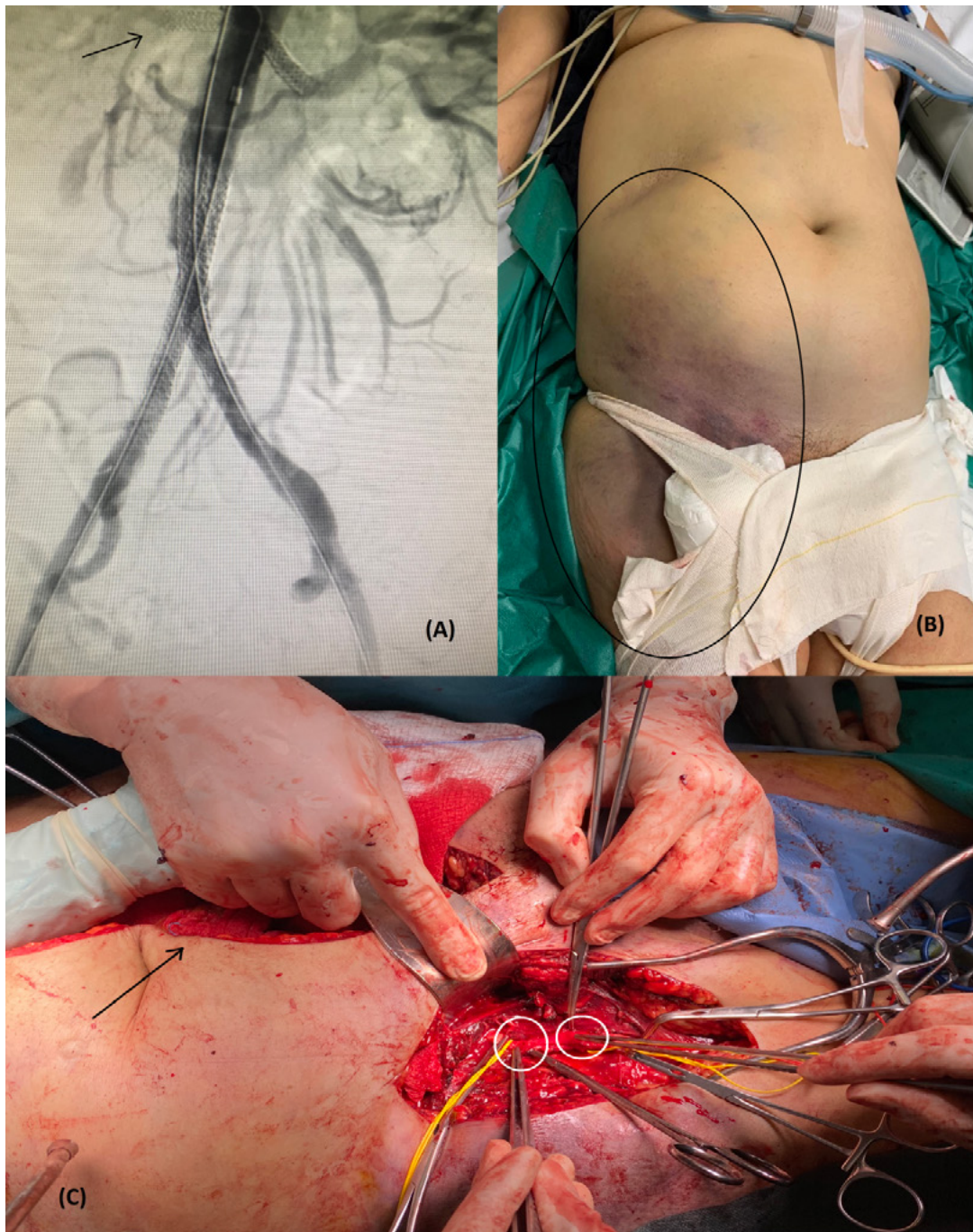


Fig 1. (A) Angiography showing the occluded right renal artery stent (arrow) and the newly placed stents (left renal artery and kissing stents); (B) Picture of the giant ruptured hematoma ranging from the right femoral region up to the right hypochondrium; (C) Intraoperative image showing the middle abdominal incision (arrow) and the two rupture points in the right

made, and the femoral bifurcation was dissected. Two rupture points were identified in the CFA and sutured with Prolen 5-0. (Figure 1C) All wounds were closed, and drains were placed both under and over the inguinal ligament. The patient was extubated and transferred to intensive care unit (ICU) for close monitoring. The patient was discharged a week after in optimal condition.

CASE 2

A 52-year-old female patient with obesity (BMI>30kg/m²),

PAD and chronic renal disease (under peritoneal dialysis) underwent a scheduled open mechanical mitral valve replacement due to severe regurgitation in our cardiac surgery department. Intraoperatively, a triple-lumen 8Fr arterial sheath was placed into the left CFA to monitor arterial pressure. Postoperatively, the sheath was removed under coumarin treatment for the valve (INR > 2.5). Possibly due to full anticoagulation and suboptimal pressure appliance, a huge expanding hematoma presented in the upper left femoral area that led to significant haemoglobin drop, severe pain and incipient skin necrosis (Figure 2A). The patient underwent a computed

angiography (CTA) illustrating a 17cmX14cm hematoma and an extravasation from the left CFA (**Figure 2B**). Before being transferred to operation room, the patient started becoming hemodynamically unstable and vasoconstriction treatment was initiated. As there was no expansion of the hematoma above the inguinal ligament, an oblique retroperitoneal approach was selected for proximal control. A second incision was made below the hematoma and superficial femoral artery was also dissected for distal control. Then, a third incision was made over the hematoma. A large amount of blood as well as thrombus were drained. During dissection of the femoral vessels, a longitudinal rupture (almost 1.5cm in length) of the common femoral vein (CFV) was identified that was sutured with Prolen 5-0. At the same level, a small rupture site of the CFA was also detected that was also sutured with Prolen 5-0. (**Figure 2C**) All wounds were closed, and 4 drains were placed

overall. The patient was extubated and transferred to ICU for close monitoring. She was discharged after 5 days from the hospital in optimal condition.

CASE 3

A 58-year-old male patient with a history of CAD underwent a scheduled percutaneous coronary intervention (PCI) in the interventional cardiology department of our institution. The procedure was conducted via a left CFA access and pressure bandages were placed after the removal of the sheath. However, the patient within the following hours presented an large expanding hematoma of the left femoral area, with the femoral circumference being almost twice the size of the contralateral limb. (**Figure 3**) The patient quickly became hemodynamically unstable, and he received 4 blood units due to significant haemoglobin drop. Without delay, the patient was transferred

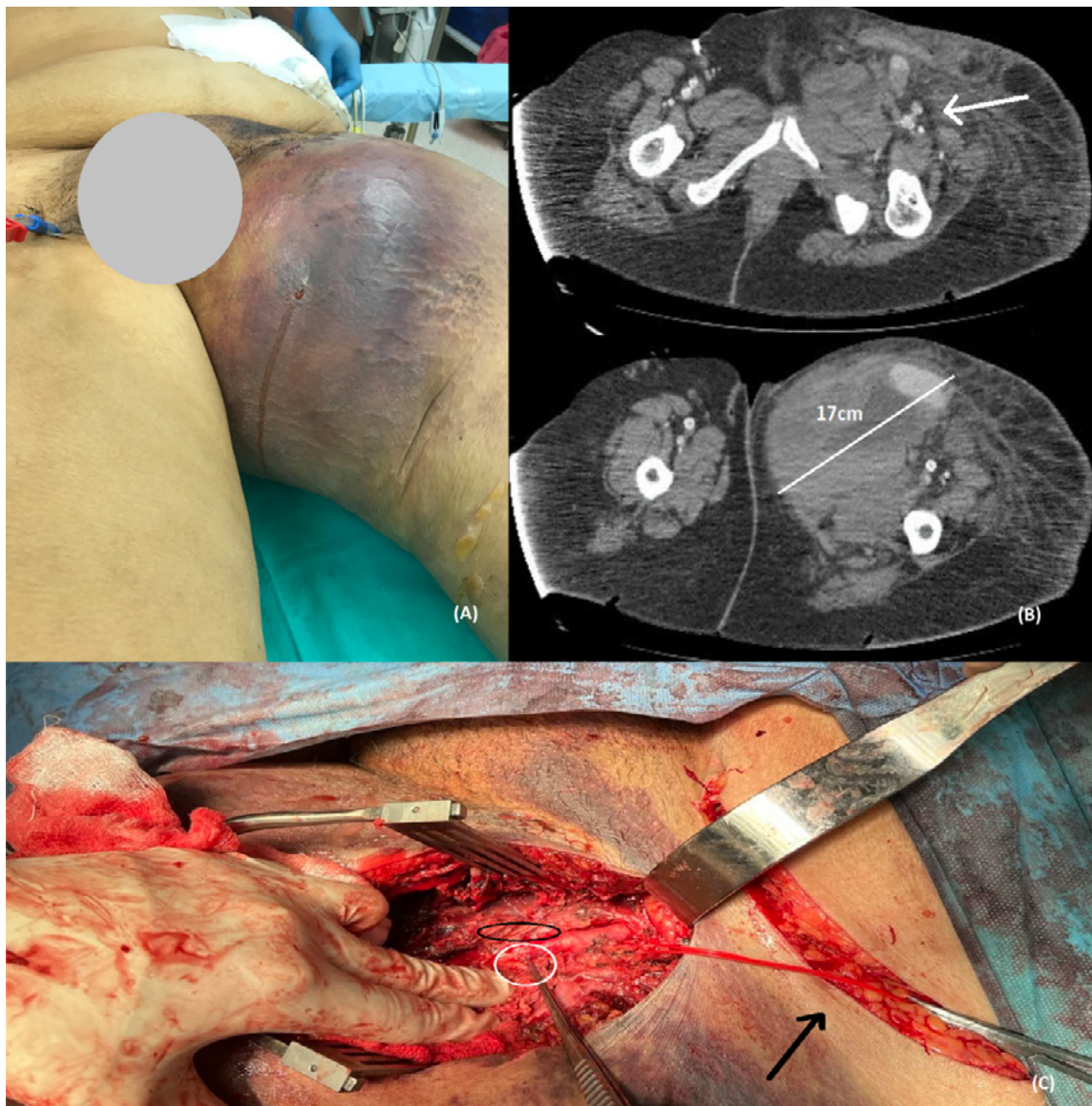


Fig 2. (A) Image of the giant left femoral hematoma causing impeding skin necrosis. (B) Images showing the extravasation from the left common femoral artery (arrow) and the maximum diameter of the hematoma; (C) Intraoperative image showing the extraperitoneal incision (arrow) and the two rupture points in the left common femoral artery (white circle) and the left common femoral vein (black circle).

to the operating room and underwent emergency surgery. Due to the size of the hematoma, an oblique extraperitoneal approach was again selected for proximal control. After controlling the external iliac artery, a femoral incision was made. Again, two rupture points were identified, one in the left CFV and one in the left CFA. Both ruptures were sutured with Prolen 5-0. The patient was stabilized and transferred to ICU for close monitoring. He was discharged within a week in optimal condition.

CASE 4

A 72-year-old patient with history of cardiac valve disease and obesity was scheduled for a transcatheter aortic valve implantation (TAVI). The procedure was conducted percuta-

neously via a left CFA access in the interventional cardiology department of our institution. After the removal of the sheath (16Fr), the cardiologists placed a percutaneous closing device twice without success. The patient quickly became unstable due to haemorrhage through the puncture site. A cut-down dissection was performed immediately within the angio-suite and clamps were placed in the left CFA to stop the bleeding. (Figure 4A) The patient then was transferred to the operating room (in another floor) and underwent an emergency surgery. The femoral bifurcation was dissected, and a severe injury of the entire CFA was detected. Therefore, the CFA was substituted with an interposition 7mm PTFE graft. (Figure 4B) The patient was stabilized and transferred to ICU for close monitoring. There were no signs of ischemia in the limb. The patient was discharged after one week in optimal condition.

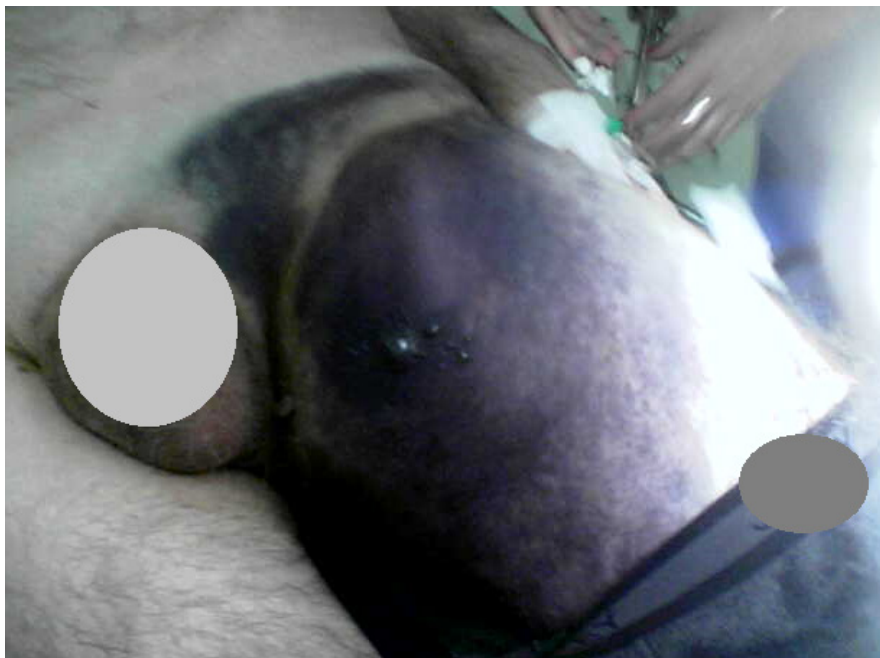

Fig 3. An expanding left femoral hematoma with a left femoral circumference almost twice as the contralateral limb.

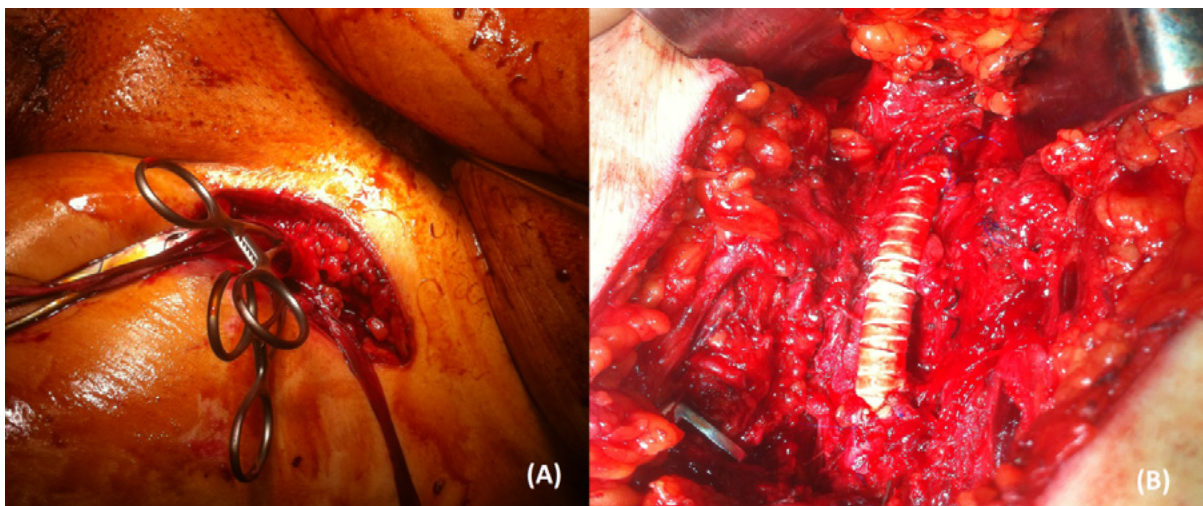


Fig 4. (A) Image showing a femoral incision and the vascular clamps placed in the left common femoral artery within the angio-suite; (B) An interposition 7mm PTFE graft placed after excision of a severely injured common femoral artery.

DISCUSSION

Arterial interventions are associated with an overall minor complication rate of less than 10%, and major complications requiring transfusion or surgical intervention occur at a rate of less than 1%.⁴ However, injury of the femoral artery is a complication with an incidence reaching up to 3.5% after transfemoral procedures in interventional cardiology and haemodialysis units.⁶ Most arterial injuries present as a pulsatile mass, and they may have a palpable thrill or an audible murmur. The diagnosis is confirmed with ultrasound imaging as first-line option.^{1,4} The ultrasound can identify the point of extravasation, the amount of thrombus, the blood flow velocity pattern and all the associations with adjacent structures. However, a further angiographic imaging may be necessary for the following reasons: a) when ultrasound is inconclusive; b) there are signs of ischemia; c) the injury is extended to the retroperitoneal area; d) an endovascular repair is planned.⁷

When the patient becomes unstable like in our cases, the indication for emergency repair is set without the need for diagnostic imaging.⁴ An injury of the CFA can cause major bleeding, PSA formation, thrombosis or distal embolization, local pain, neuropathy or local skin necrosis.⁶ Risk factors include large-sized catheters, false technique, obesity, haemodialysis, hypertension, anticoagulation and PAD, concurring with our cases.⁶ Patients treated for CAD or valve disease usually receive large doses of antiplatelets or anticoagulants that increase the risk for bleeding as well. Furthermore, patients with chronic renal disease may have also some degree of coagulopathy.⁷

Life-threatening IVIs of the femoral artery are rare in general, but they can be devastating.⁶ In a recent study evaluating life-threatening IVIs, however, groin was the most common location (42%).⁸ Considering each specialty, IVIs were detected in the groin in 66% of interventional radiology cases and in 33% of thoracic surgery cases, concurring with our report.⁸ Additionally, transfemoral access is associated with higher mortality compared to transradial access for endovascular repair of PAD or carotid disease.⁹ It seems that death if occurs, it is not attributable to the injury itself in all cases. However, almost half of the injuries are considered avoidable with possible causes including false communication, doctor's delay, technical false, false patient selection or indication.^{8,10} In our cases, the use of ultrasonographic guidance, a more careful pressure appliance, or the use of a closing device could have prevented major bleeding in some of the patients. In addition, a vascular surgeon was not informed preoperatively in all the cases and that may have impacted the outcome significantly. We have found in an earlier study that a standardized preoperative evaluation by a vascular surgeon was associated with a lower mortality risk among patients undergoing TAVI.¹⁰ Even after the injury, delay in obtaining vascular surgery assistance may lead to unnecessary blood loss or additional vascular damage.⁹

Non-surgical treatment remains the primary management for femoral IVIs when the patients are asymptomatic and the diameter of the PSA is < 2cm. Indications for open surgery in-

clude hemodynamic instability of the patient, rapid expansion of a hematoma/PSA, mycotic infection of a PSA, compromised soft tissue viability, failure of more conservative strategies, concomitant distal ischemia and neurological deficit due to local pressure.^{1,2,5} Conservative management may be also preferred in patients with many comorbidities and significant anaesthetic risk. This management must include restoration of the patient's haemostatic function, lowering blood pressure, possible transfusions and absolute bed rest. Of course, frequent haemoglobin measurements and close clinical assessment are essential so that the plan may be changed promptly to surgical treatment if necessary.^{1,2,5} The success rate of conservative treatment is significantly lower compared to surgery although the complications rate is higher after surgical repair.⁵ When comparing conservative strategies, it seems that UGTI has superior results compared to ultrasound-guided compression.⁵ UGTI may be associated with rare complications such as peripheral embolization, anaphylactic reaction to thrombin and skin infection. Some data indicate that sac area and neck length/width is associated with the success of UGTI.⁵

When intervention is indicated, open surgery is usually reserved for rupture or expanding PSAs. Although endovascular treatments (covered stent placement or coil embolization) are currently used in many cases, their efficacy and safety have been shown only in small studies.⁵ Almost half of femoral IVIs are treated with simple suture of the vessel like in our cases.⁷ When the damage is more extent, a more complex repair may be needed such as end-to-end anastomosis, patch placement, bypass or interposition grafting. Vascular injuries have a better prognosis when treated quickly after injury. In cases of large hematomas with possible retroperitoneal expansion, a proximal external iliac artery dissection and control should be used whereas in cases with obvious bleeding below the inguinal ligament, dissection of the CFA only may be adequate for controlling the bleeding. In some cases, a concomitant venous injury may be present that can cause major bleeding despite the proximal arterial control concurring with our report.⁴ In these cases, the attempt to obtain vascular control with forceful use of clamps may result in additional injuries compared to achieving haemostasis with compression. Digital compression or the use of swabs may be a more appropriate strategy for venous injuries.

In conclusion, the majority of IVIs in the femoral area are avoidable and a standardized preoperative evaluation by a vascular surgeon may prevent them. They should be treated with open repair promptly when they are expanding, ruptured or complicated. Especially in cases of rapid retroperitoneal expansion of a hematoma or giant-sized PSAs, a proximal control above the inguinal ligament should limit the blood loss. Caution should be taken as a concomitant major venous injury may be present and increase the amount of blood lost.

REFERENCES

- 1 Filis K, Sigala F, Stamatina T, Georgias D, Zografos G, Galyfos G. Iatrogenic Vascular Injuries of the Abdomen and Pelvis: The Experience at a Hellenic University Hospital. *Vasc Endovascular Surg.* 2019;53:541-546.

- 2 Filis K, Arhontovasilis F, Theodorou D, Albanopoulos K, Lagoudianakis E, Manouras A, Vavuranakis M, Vlachopoulos C, Toutouzas K, Tsiamis E, Androulakis A, Kallikazaros I, Giannopoulos A, Bramis I, Stefanadis C. Management of early and late detected vascular complications following femoral arterial puncture for cardiac catheterization. *Hellenic J Cardiol.* 2007;48:134-42.
- 3 DeRubertis BG, Faries PL, McKinsey JF, Chaer RA, Pierce M, Karwowski J, et al. Shifting paradigms in the treatment of lower extremity vascular disease: a report of 1000 percutaneous interventions. *Ann Surg.* 2007;246:415-24..
- 4 Ge BH, Copelan A, Scola D, Watts MM. Iatrogenic percutaneous vascular injuries: clinical presentation, imaging, and management. *Semin Intervent Radiol.* 2015;32:108-22.
- 5 Wu H, Zhang L, Zhang C, Xie B, Lou C, Liu Y, Bai H. Non-Surgical treatment Versus Surgery for Iatrogenic Femoral Artery Pseudoaneurysms: Systematic Review and Meta-Analysis. *Front Surg.* 2022;9:905701.
- 6 Kulkarni LM, Sirsat SM. Ruptured femoral artery pseudoaneurysm: A life-threatening, iatrogenic catastrophe! *Indian J Anaesth.* 2016;60:437-9.
- 7 Rammos C, Rassaf T. Insight in the treatment of iatrogenic femoral artery pseudoaneurysms. *Vasa.* 2021;50:163-164.
- 8 Rudström H, Bergqvist D, Björck M. Iatrogenic vascular injuries with lethal outcome. *World J Surg.* 2013;37:1981-7.
- 9 Galyfos G, Sigala F, Filis K. Transradial versus Transfemoral access in patients undergoing peripheral artery angioplasty/stenting: A meta-analysis. *Cardiovasc Revasc Med.* 2018;19:457-465.
- 10 Filis K, Galyfos G, Sigala F, Karantzikos G, Vavouranakis M, Toutouzas K, Albanopoulos K, Zografos G. Vascular complications during transcatheter aortic valve implantation: The role of the vascular surgeon. *Vascular.* 2020;28:421-429.

Preservation of internal iliac artery by using it as target vessel for distal anastomosis of bifurcated aortic grafts during surgical repair of aorto-iliac aneurysms

Stella Lioudaki, Nikolaos Kontopodis, George Tzouliadakis, Emmanouil Tavlas, Alexandros Kafetzakis, Christos V. Ioannou

Vascular Surgery Unit, Department of Vascular and Cardiothoracic Surgery, University of Crete, Medical School, Heraklion, Crete, Greece

Abstract:

Common iliac artery aneurysms coexist with abdominal aortic aneurysms in 20-30% of cases and may present technical challenges during surgical reconstruction. Rarely, wide iliac bifurcations may be encountered which may render construction of the distal anastomosis in the iliac bifurcation not feasible. In this instance several techniques may be used, but our preferred approach is the anastomosis of the graft in the internal iliac with subsequent transposition of the external iliac artery in the graft limb. We describe this technique in 3 patients. Postoperative course was uneventful with no signs of pelvic or lower limb ischemia and 100% primary patency during 15 months. In conclusion, the anastomosis of the limb of a bifurcated graft with the internal and transposition of the external iliac artery onto the graft limb may simplify aorto-iliac reconstruction in case of wide iliac bifurcations and safely preserve flow in both internal and external iliac arteries.

INTRODUCTION

Open abdominal aortic aneurysm (AAA) repair is a major surgical procedure, which presents specific technical challenges when common iliac arteries (CIA) are involved (20-30% of cases).¹ Preservation of blood flow to at least one internal iliac artery (IIA) is crucial, since bilateral occlusion is related to a high complication rate, such as buttock claudication, intestinal ischemia and erectile dysfunction.^{2,3} Typically, in the presence of a CIA aneurysm the distal anastomosis is performed on the iliac bifurcation, including both the orifices of IIA and external iliac artery (EIA). Rarely, this is not technically feasible, either because of the distance between the two orifices or the existence of an aneurysmal IIA orifice. In these cases the technique that has been mainly reported is constructing the distal anastomosis with the EIA and performing a jump graft to the IIA, although data are scarce.^{4,5} An alternative technique that may be used and simplify the procedure is to anastomose the graft limb with the IIA and then transpose the EIA onto the graft. We present three cases in which this approach was used.

Author for correspondence:

Nikolaos Kontopodis, MD, MSc, PhD

Vascular Surgery Unit, Department of Cardiothoracic and Vascular Surgery, University Hospital of Heraklion, University of Crete Medical School, PO-Box 1352, 711 10, Heraklion, Greece

Tel: +30 2810392393

Tel: +30 6948202539

E-mail: kontopodisn@yahoo.gr, nkontopodis@uoc.gr

doi: 10.59037/vrfypw81

ISSN 2732-7175 / 2023 Hellenic Society of Vascular and Endovascular Surgery Published by Rotonda Publications
All rights reserved. <https://www.heljves.com>

CASE REPORT/TECHNIQUE

First case regards a 55-year old male patient presenting an aorto-iliac aneurysm with maximum aortic diameter of 87mm, right CIA of 56mm and left CIA of 86 mm. On the left side the origins of EIA and IIA were apart (**Figure 1A and 1B**). The patient was treated with open repair, anastomosing the right graft limb with the iliac bifurcation whereas on the left side it was anastomosed with the left IIA and the EIA was transposed on the graft limb.

Second case regards a 67-year-old man suffering from a small 40mm AAA, and bilateral CIAs aneurysms with a maximum diameter of 70mm. **Figure 2A and 2B** present the pre-operative CT angiography indicating the long distance between the origins of EIA and IIA in both sides. **Figure 2C** displays the postoperative CT angiography indicating ligation of left IIA and anastomosis of the graft to the left EIA while the right IIA was preserved by anastomosing the right graft limb to IIA followed by transposition of right EIA on the graft.

Third case is a patient with a 40mm AAA and bilateral 60mm CIA aneurysms and wide iliac bifurcations bilaterally. **Figure 3A and 3B** presents the pre-operative CT. **Figure 3C** displays the 3-Dimensional reconstruction of the postoperative CT angiography with ligation of the right IIA and graft anastomosis to left IIA, and left EIA transposition.

All patients had an uneventful postoperative course. No signs of pelvic or lower limbs ischemic complications were noted. Furthermore, patients presented a free walking ability with no buttock claudication. During a mean follow-up of 15months primary patency of grafts and iliac vessels was 100%.

DISCUSSION

In this report our preferred treatment strategy during open

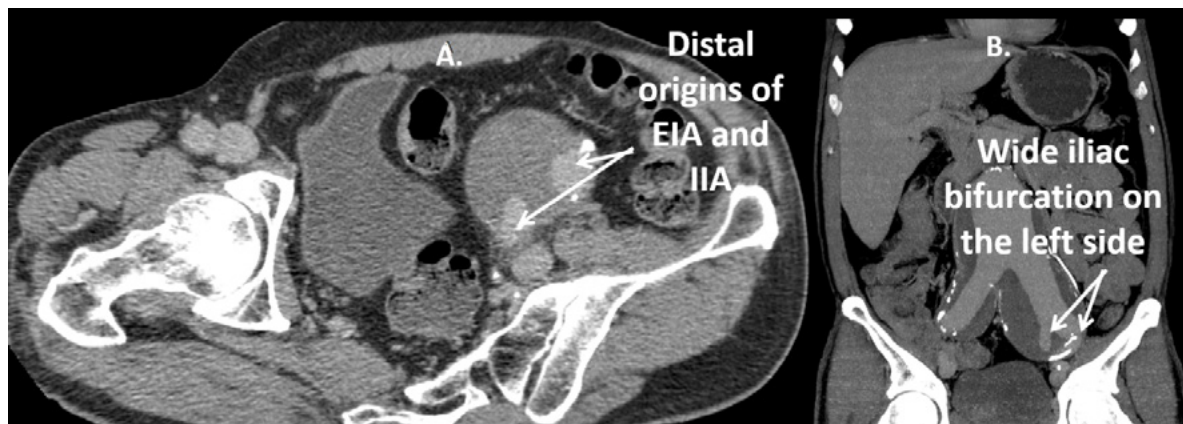


Figure 1: Axial (1A) and coronal (1B) views of the 1st patient, showing the wide left iliac bifurcation.

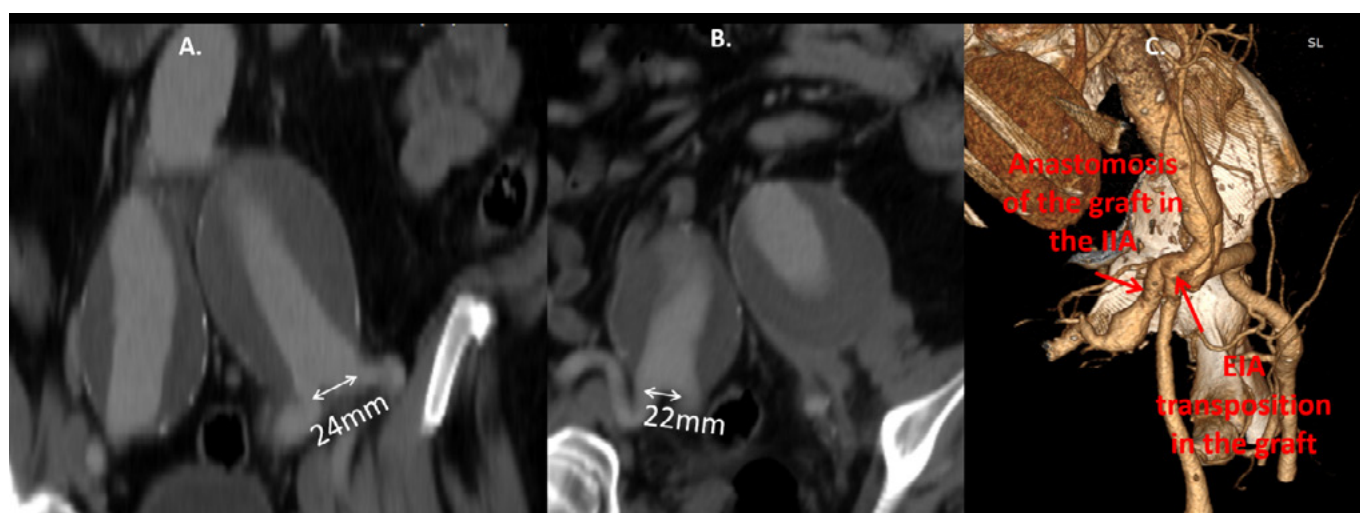


Figure 2: Coronal views indicating wide left (2A) and right (2B) iliac bifurcations and 3-Dimensional reconstruction of the post-operative CT angiography (2C), of 2nd patient.

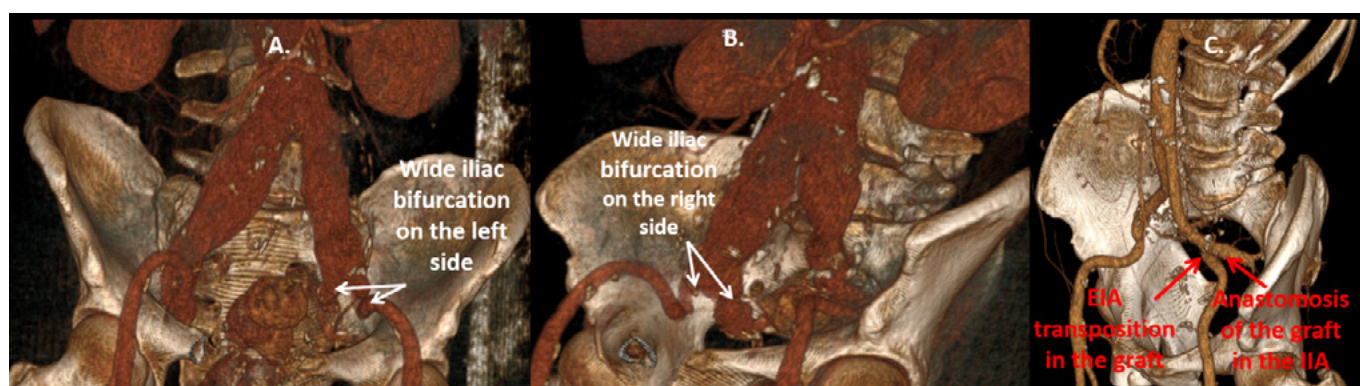


Figure 3: 3-Dimensional reconstruction indicating wide iliac bifurcations on left (3A) and right (3B) side and the postoperative CT scan (3C) of the 3rd case.

surgical reconstruction of aorto-iliac aneurysms with wide iliac bifurcations is presented. This involves construction of the distal anastomosis in the IIA and subsequent transposition of the EIA onto the graft limb. This approach facilitates the preservation of both IIA and EIA without adding specific technical difficulties in the procedure. In our opinion, the opposite se-

quence (i.e. construction of the distal anastomosis in the EIA and transposition of the IIA) would be far more demanding, especially in cases that the IIA lies deep in the pelvis and in a posterior position relative to the EIA. For example, in all three cases reported in the current study (Figures 1A, 2C, 3C) it can be seen that the anastomosis of the IIA origin would be re-

quired to be constructed in the posterior side of the graft limb. Therefore, our proposed technique to make the anastomosis of the graft in the IIA and transpose the EIA, may be particularly useful in patients with a deep and posterior IIA location.

Notably, we were not able to identify previous reports on this technique although it is possible that vascular surgeons might use this approach at an empirical fashion. Moreover, we could not retrieve any data on the frequency of an aorto-iliac anatomy that does not allow the inclusion of the EIA and IIA orifices in one anastomosis. According to our experience, this is a rare occasion which was encountered in only 3 cases, among 51 elective aortoiliac reconstructions for AAAs, during a 3-year period. As expected, no specific thresholds to define wide iliac bifurcations exist, but in the current series a distance >2cm between the origins of the division branches was recorded in all 3 cases.

An alternative technique which would be suitable for these cases is external to internal iliac bypass which again has only been scarcely reported in the literature, with most data regarding endovascular treatment of AAAs that need extension of the endograft in the EIA due to wide CIAs.^{6,7} For these cases, an excellent patency of these grafts has been reported but data are available for a short follow-up of a few months. In our cases during a mean follow-up of 15 months primary patency of grafts and native iliac arteries was universal and no symptoms of pelvic or limb ischemia were reported. Notably, in these patients ligation of the CIA and femoro-femoral bypass in order to ensure reverse flow in the IIA was not feasible due to the distance between the origins of the IIA and EIA. Moreover, it should be underlined that endovascular repair was not preferred in these patients because of their young age and good general health status which made them suitable candidates for open surgery.

In conclusion, the anastomosis of the limb of a bifurcated graft with the IIA and transposition of EIA onto the graft limb is a safe technique to facilitate the preservation of the IIA when

anastomosis with the iliac bifurcation is not feasible.

REFERENCES

- 1 Ziegler P, Avgerinos ED, Umscheid T, Perdikides T, Erz K, Stelter WJ. Branched iliac bifurcation: 6 years experience with endovascular preservation of internal iliac artery flow. *J Vasc Surg.* 2007;46:204-10.
- 2 Kouvelos GN, Katsargyris A, Antoniou GA, Oikonomou K, Verhoeven EL. Outcome after Interruption or Preservation of Internal Iliac Artery Flow During Endovascular Repair of Abdominal Aorto-iliac Aneurysms. *Eur J VascEndovasc Surg.* 2016;52:621-634.
- 3 Kudo T. Surgical Complications after Open Abdominal Aortic Aneurysm Repair: Intestinal Ischemia, Buttock Claudication and Sexual Dysfunction. *Ann Vasc Dis.* 2019;12:157-162.
- 4 Hosaka A, Kato M, Kato I, Isshiki S, Okubo N. Outcome after concomitant unilateral embolization of the internal iliac artery and contralateral external-to-internal iliac artery bypass grafting during endovascular aneurysm repair. *J Vasc Surg.* 2011;54:960-4.
- 5 Mansukhani NA, Havelka GE, Helenowski IB, Rodriguez HE, Hoel AW, Eskandari MK. Hybrid Endovascular Aortic Aneurysm Repair: Preservation of Pelvic Perfusion with External to Internal Iliac Artery Bypass. *Ann Vasc Surg.* 2017;42:162-168.
- 6 Kobayashi Y, Sakaki M, Yasuoka T, Iida O, Dohi T, Uematsu M. Endovascular repair with contralateral external-to-internal iliac artery bypass grafting: a case series. *BMC Res Notes.* 2015;8:183.
- 7 Unno N, Inuzuka K, Yamamoto N, Sagara D, Suzuki M, Konno H. Preservation of pelvic circulation with hypogastric artery bypass in endovascular repair of abdominal aortic aneurysm with bilateral iliac artery aneurysms. *J Vasc Surg.* 2006;44:1170-5.

Multiple skip incisions technique for two-staged basilic vein transposition: a good alternative to the standard single long incision

Pavlos Georgiou, Christos Pitros, Andreas Tsimpoukis, Spyros Papadoulas

Vascular Surgery Department, Patras University Hospital, Patras-Greece

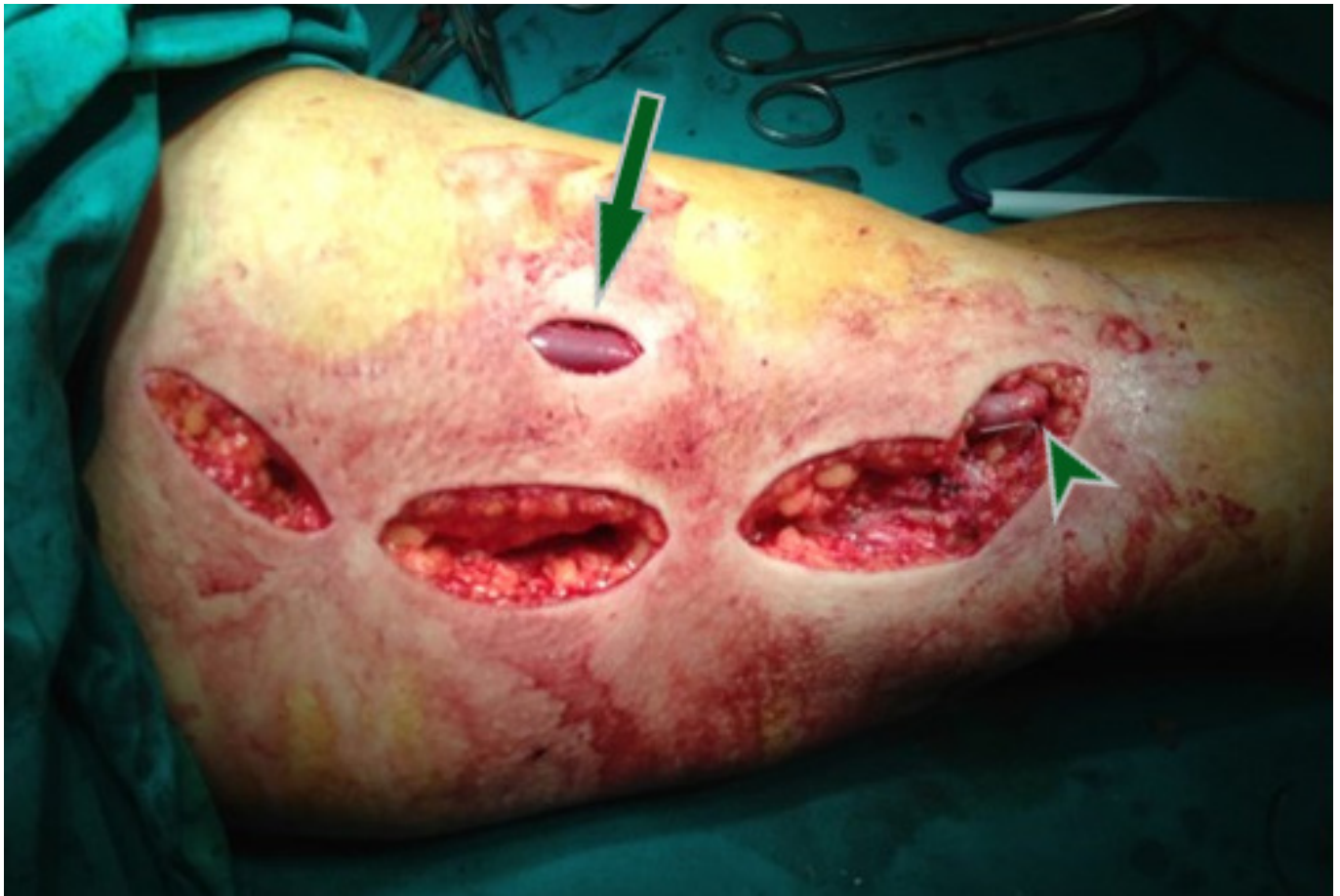


Figure: The basilic vein was transected and transposed to an antero-lateral subcutaneous channel after three skip incision to harvest the vein (arrow). Finally, the venous parts were re-anastomosed (arrowhead).

A 58-year-old-male on hemodialysis underwent a two-staged tunneled basilic vein transposition with three skip incisions. Initially, preoperative color-duplex mapping was performed and a standard brachio-basilic arteriovenous fistula with the median cubital vein was accomplished. Six weeks later, after the arterialization of the basilic vein, the second stage took

place after skin marking of basilic vein's location by ultrasound. Under local anesthesia, the basilic vein and the cubital vein were dissected free from the arterial anastomosis up to the confluence with the axillary vein, using hook/right-angle retractors to dissect the vein under the skin. The vein was transected peripherally, tunneled subcutaneously in a new lateral route, after a small skin incision in the mid-upper arm, and re-anastomosed. The incisions were closed in a standard fashion. The access is still functional during the last six years.

Multiple skip incisions compared to a single long incision have a better cosmetic result and cause less tissue damage. A single incision offers easier vein dissection, needs less operative time but leaves back a longer scar. Multiple skip incisions technique would have the theoretical advantage of reduced postoperative pain, oedema and surgical site infection/dehis-

Author for correspondence:

Spyros Papadoulas, MD, MSc, PhD

Vascular Surgery Department, Patras University Hospital,
26504, Rio, Patras, Greece

E-mail: spyros.papadoulas@gmail.com

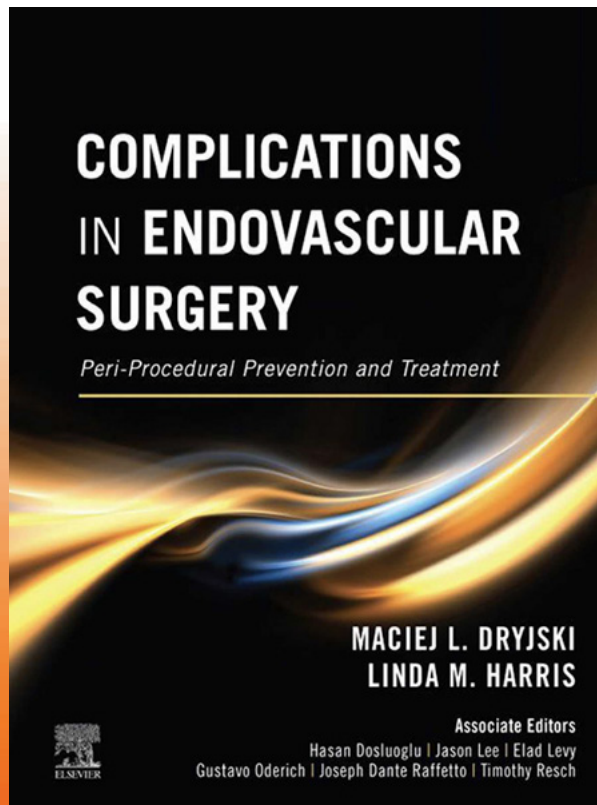
doi: 10.59037/xfhsga57

ISSN 2732-7175 / 2023 Hellenic Society of Vascular and
Endovascular Surgery Published by Rotonda Publications
All rights reserved. <https://www.heljves.com>

cence rates. This is supported in some reports¹ but in others, although these complications were encountered infrequently, the difference did not reach statistical significance.²

REFERENCES

- 1 Jairath A, Singh A, Sabnis R, Ganpule A, Desai M. Minimally invasive basilic vein transposition in the arm or forearm for autogenous haemodialysis access: A less morbid alternative to the conventional technique. *Arab J Urol*. 2017 Mar 6;15(2):170-176. doi: 10.1016/j.aju.2017.01.004. PMID: 29071148; PMCID: PMC5653617.
- 2 Shaikh FA, Nazeer S, Sophie Z, Shahzad N, Siddiqui NA. Multiple Skip Incisions Versus Single Long Incision for Single-stage Basilic Transposition Arteriovenous Fistula: A Cohort Study. *Ann Vasc Surg*. 2018 Jul;50:135-139. doi: 10.1016/j.avsg.2018.01.083. Epub 2018 Mar 5. PMID: 29518500.



Publication Date: 04/2021

PRICE: 190€

As devices, technologies, and imaging techniques continue to evolve, today's endovascular surgical techniques have increased in both number and complexity. *Complications in Endovascular Surgery* provides a unique focus on potential complications encountered in the operating room, preparing you to anticipate the unexpected, identify the risk factors in individual procedures, and take steps to successfully manage complications when they occur.



Rotonda Publications

8 Kamvounion Str, 54621 Thessaloniki, Greece

Tel: +30 2310 212 212, +30 2310 285 785, Fax: +30 2310 280 287

www.ipokratis.gr

e-mail: ipokratis@ipokratis.gr

Hellenic Journal of Vascular and Endovascular Surgery

- Submit your paper at journal's official site:
<https://heljves.com/>
- No fees for paper submission and publication
- Open access to all of journal's content



Hellenic Society of
Vascular and Endovascular Surgery